Chapter 30

The Vascular Biology of Atherosclerosis

PETER LIBBY

STRUCTURE OF THE NORMAL ARTERY...995
The Intima.....995
The Tunica Media.....996
The Adventitia.....996
INITIATION OF ATHEROSCLEROSIS.....996
Extracellular Lipid Accumulation.....996
Leukocyte Recruitment.....997
The Focality of Lesion Formation.....999
Intracellular Lipid Accumulation: Foam Cell Formation.....999
THE EVOLUTION OF ATHEROMA..... 1000
Smooth Muscle Cell Migration and Proliferation..... 1000
Smooth Muscle Cell Death During Atherogenesis..... 1000
The Arterial Extracellular Matrix..... 1001
Angiogenesis in Plaques..... 1001
Plaque Mineralization..... 1001
COMPLICATIONS OF ATHEROSCLEROSIS..... 1001
Arterial Stenoses and Their Clinical Implications..... 1001
Thrombosis and Atheroma Complication..... 1002
SPECIAL CASES OF ARTERIOSCLEROSIS..... 1004
Restenosis after Arterial Intervention..... 1004
Accelerated Arteriosclerosis after Transplantation..... 1004
Aneurysmal Disease..... 1005
Infection and Atherosclerosis..... 1006
REFERENCES..... 1006

A remarkable evolution in concepts concerning the pathogenesis of atherosclerosis occurred in the 20th century. This disease has a venerable history, having left traces in the arteries of Egyptian mummies.[1] Apparently uncommon in antiquity, atherosclerosis became epidemic as populations increasingly survived early mortality caused by infectious diseases and as many societies adopted dietary habits that may promote atherosclerosis.

At the end of the 19th century, the first edition of Osler's *Textbook of Medicine* articulated a rather fatalistic view of atheroma as an inevitable degenerative process that affected arteries, which were structures viewed by many of his contemporaries as mere conduits: "In the make-up of the machine bad material was used in the tubing."[2] Indeed, until very recently internists and cardiologists generally viewed arteries as inanimate tubes rather than living, dynamic tissue. Over 100 years ago, Virchow recognized the participation of cells in atherogenesis. A controversy raged between Virchow, who viewed atheroma as a proliferative disease,[3] and Rokitansky, who believed that atheroma derived from healing and resorption of thrombi.[4] In the early part of the 20th century, Anitschkow and Chalatow used dietary modulation to produce fatty lesions in the arteries of rabbits and ultimately identified cholesterol as the culprit.[5] These observations, followed by the characterization of human lipoprotein particles at mid century, promoted the concept of insudation of lipids as a cause for atherosclerosis. At the beginning of the new millennium, we have learned enough about atherosclerosis to recognize that elements of all of these pathogenic theories participate in atherogenesis. This chapter summarizes evidence from human studies, animal experimentation, and in vitro work, and highlights a synoptic view of atherogenesis, taking into account advances in vascular biology that have enabled us to achieve a deeper understanding of the process.

Acquaintance with the vascular biology of atherosclerosis should prove useful to the practitioner. Our daily contact with this common disease lulls us into a complacent belief that we understand it better than we actually do. For example, we are just beginning to learn why atherosclerosis affects certain regions of the arterial tree preferentially and why its clinical manifestations occur only at certain times. Atherosclerosis can involve both large and medium-sized arteries diffusely. Postmortem and intravascular ultrasound studies have revealed widespread intimal thickening in patients with atherosclerosis and, indeed, in many asymptomatic human adults.[6] At the same time, atherosclerosis is a focal disease that constricts some areas of affected vessels much more than others. Understanding of the biological basis of the predilection of certain sites to develop atheroma is just beginning to emerge.[7]

Atherosclerosis also displays heterogeneity in time, being a disease with both chronic and acute manifestations. Few human diseases have a longer "incubation" period than atherosclerosis, which begins to affect arteries of many North Americans in the second and third decades of life (Fig. 30–1).[7a, 7b] Yet typically, symptoms of atherosclerosis do not occur until several decades later, characteristically occurring even later in women. Despite this indolent time course and prolonged period of clinical inactivity, the dreaded complications of atheroma such as myocardial infarction, unstable angina, or stroke typically occur suddenly.

Another poorly understood aspect of atherogenesis is its role in causing narrowing, or stenosis, of some vessels and ectasia of others. Typically, we fear stenoses in coronary atherosclerosis. However, aneurysm is a common manifestation of this disease in other vessels, including the aorta. Even in the life history of a single atherosclerotic lesion, a phase of ectasia known as positive remodeling, or compensatory enlargement, precedes the formation of stenotic lesions.[8, 9] Contemporary vascular biology is beginning to shed light on some of these apparent contradictions, or paradoxes, in understanding atherosclerosis.

STRUCTURE OF THE NORMAL ARTERY

The Intima

Understanding the pathogenesis of atherosclerosis first requires knowledge of the structure and biology of the normal artery and its indigenous cell types. Normal arteries have a well-developed trilaminar structure (Fig. 30–2). The innermost layer, the tunica intima, is thin at birth in humans and many nonhuman species. Although often depicted as a monolayer of endothelial cells abutting directly on a basal lamina, the structure of the adult human intima is actually much more complex and heterogeneous. The endothelial cell of the arterial intima constitutes the crucial contact surface with blood. Arterial endothelial cells possess many highly regulated mechanisms of capital importance in vascular homeostasis that often go awry during the pathogenesis of arterial diseases.

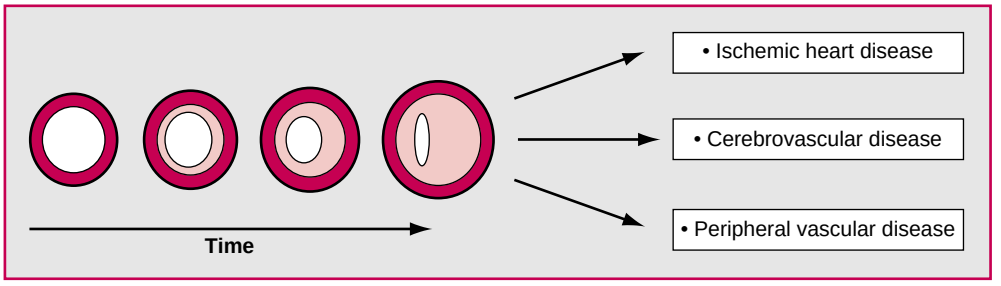

FIGURE 30–1. A schematic life history of an atherosclerotic lesion. In westernized societies, and increasingly in developing countries, atherogenesis begins in early life. Lesion evolution usually occurs slowly over decades, often progressing in a asymptomatic manner or eventually causing stable symptoms related to embarrassment of flow, such as angina pectoris or intermittent claudication. For the first part of the life history of the lesion, growth proceeds abluminally, in an outward direction preserving the lumen (compensatory enlargement or "positive remodeling"). A minority of lesions will produce thrombotic complications, leading to clinical manifestations such as the unstable coronary syndromes, thrombotic stroke, or critical limb ischemia.

FIGURE 30–2. See color plate 17.

FIGURE 30–3. See color plate 18.

For example, the endothelial cell provides one of the only surfaces, either natural or synthetic, that can maintain blood in a liquid state during protracted contact (Fig. 30–3). This remarkable blood compatibility derives in part from the expression of heparan sulfate proteoglycan molecules on the surface of the endothelial cell. These molecules, like heparin, serve as a cofactor for antithrombin III, causing a conformational change that allows this inhibitor to bind to and inactivate thrombin. The surface of the endothelial cell also contains thrombomodulin, which binds thrombin molecules and can exert antithrombotic properties by activating proteins S and C. Should a thrombus begin to form, the normal endothelial cell possesses potent fibrinolytic mechanisms associated with its surface. In this regard, the endothelial cell can produce both tissue and urokinase type plasminogen activators. These enzymes catalyze the activation of plasminogen to form plasmin, a fibrinolytic enzyme. (For a complete discussion of the role of endothelium in hemostasis and fibrinolysis, see Chap. 62.)

The endothelial monolayer rests upon a basement membrane containing nonfibrillar collagen types, such as type IV collagen, laminin, fibronectin, and other extracellular matrix molecules.[10] With aging, human arteries develop a more complex intima containing arterial smooth muscle cells and fibrillar forms of interstitial collagen (types I and III). The smooth muscle cell produces these extracellular matrix constituents of the arterial intima. The presence of a more complex intima, known by pathologists as diffuse intimal thickening, characterizes most adult human arteries. Some locales in the arterial tree tend to develop thicker intimas than other regions, even in the absence of atherosclerosis.[11] For example, the proximal left anterior descending coronary artery often contains an intimal cushion of smooth muscle cells more fully developed than that in typical arteries. (See also Chap. 41.) The diffuse intimal thickening process does not necessarily go hand in hand with lipid accumulation and may occur in individuals without substantial burdens of atheroma. The internal elastic membrane bounds the tunica intima abluminally and serves as the border between the intimal layer and the underlying tunica media.

The Tunica Media

The tunica media lies under the media and internal elastic lamina. The media of elastic arteries such as the aorta have well-developed concentric layers of smooth muscle cells, interleaved with layers of elastin-rich extracellular matrix (see Fig. 30–2*A*). This structure appears well adapted to the storage of the kinetic energy of left ventricular systole by the walls of great arteries. The lamellar structure also doubtless contributes to the structural integrity of the arterial trunks. The media of smaller muscular arteries usually have a less-stereotyped organization (see Fig. 30–2*B*). Smooth muscle cells in these smaller arteries generally reside within the surrounding matrix in a more continuous than lamellar array. The smooth muscle cells in normal arteries are generally quiescent from the standpoint of growth control. That is, rates of cell division and cell death are quite low.[12] In the normal artery, a state of homeostasis of extracellular matrix also typically prevails. Because extracellular matrix neither accumulates nor atrophies, rates of matrix synthesis and dissolution must balance each other under normal conditions. The external elastic lamina bounds the tunica media abluminally, forming the border with the adventitial layer.

The Adventitia

The adventitia of arteries has typically received little attention, although appreciation of its potential roles in arterial homeostasis and pathology has recently increased. The adventitia contains collagen fibrils in a looser array than usually encountered in the intima. Vasa vasorum and nerve endings localize in this outermost layer of the arterial wall. The cellular population in the adventitia is more sparse than in other arterial layers. Cells encountered in this layer include fibroblasts and mast cells (see Fig. 30–2).

INITIATION OF ATHEROSCLEROSIS

Extracellular Lipid Accumulation

The first steps in atherogenesis in humans remain largely conjectural. However, integration of observations of tissues obtained from young humans with the results of experimental studies of atherogenesis in animals provides hints in this regard. On initiation of an atherogenic diet rich in cholesterol and saturated fat, one of the first ultrastructural alterations is an accumulation of small lipoprotein particles in the intima (Fig. 30–4,*1*).[13] These lipoprotein particles appear to decorate the proteoglycan of the arterial intima and tend to coalesce into aggregates (Fig. 30–5).[14, 15] Detailed kinetic studies of labeled lipoprotein particles indi-

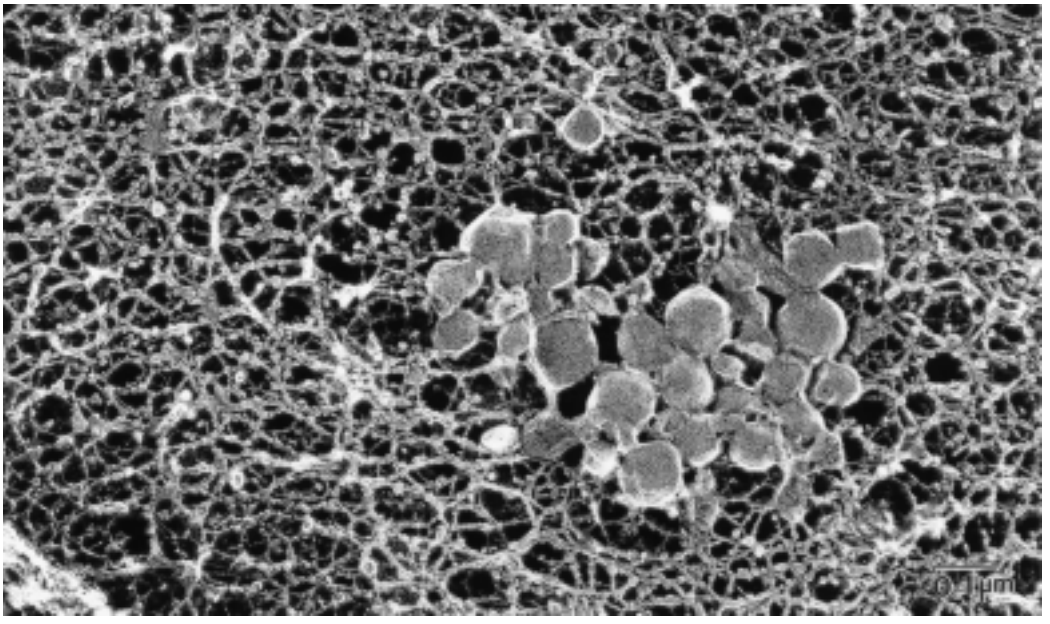

FIGURE 30–5. Scanning electron micrograph of a freeze etch preparation of rabbit aorta that received an intravenous injection of human low-density lipoprotein (LDL). Round LDL particles decorate the strands of proteoglycan found in the subendothelial region of the intima. By binding LDL particles, proteoglycan molecules can retard their traversal of the intima and promote their accumulation. Proteoglycan-associated LDL appears particularly susceptible to oxidative modification. Accumulation of extracellular lipoprotein particles is one of the first morphological changes noted after initiation of an atherogenic diet in experimental animals. (From Nievelstein PF, Fogelman AM, Mottino G, et al: Lipid accumulation in rabbit aortic intima 2 hours after bolus infusion of low density lipoprotein: A deep-etch and immunolocalization study of ultrarapidly frozen tissue. Arterioscler Thromb Vasc Biol 11:1795–1805, 1991.)

FIGURE 30–4. See color plate 18.

cate that a prolonged residence time characterizes sites of early lesion formation in rabbits. [16, 17] The binding of lipoproteins to proteoglycan in the intima captures and retains these particles, accounting for their prolonged residence time.[15, 18] Lipoprotein particles bound to proteoglycan appear to exhibit increased susceptibility to oxidative or other chemical modifications, considered by many to be an important component of the pathogenesis of early atherosclerosis (see Fig. 30–4,*2*).[15, 19–21] Other studies suggest that permeability of the endothelial monolayer increases at sites of lesion predilection to low-density lipoprotein (LDL).[22] Contributors to oxidative stress in the nascent atheroma could include the nicotinamide adenine dinucleotide and nicotinamide adenine dinucleotide phosphate-dependent oxidases expressed by vascular cells[23] and lipoxygenases expressed by infiltrating leukocytes.[24] In addition to oxidation, aggregation, enzymatic processing due to sphingomyelinase, and glycation (see Chap. 63) can modify LDL in the intima.

Leukocyte Recruitment

The second morphologically definable event in the initiation of atheroma is leukocyte recruitment and accumulation (see Fig. 30–4,*3*). The normal endothelial cell generally resists adhesive interactions with leukocytes. Even in inflamed tissues, most recruitment and trafficking of leukocytes occurs in postcapillary venules, not in arteries. However, very early after initiation of hypercholesterolemia, leukocytes adhere to the endothelium and diapedese between endothelial cell junctions to enter the intima, where they begin to accumulate lipids and transform into foam cells (Fig. 30–6).[25] In addition to the monocyte, T lymphocytes also tend to accumulate in early human and animal atherosclerotic lesions.[26, 27]

The expression of certain leukocyte adhesion molecules on the surface of the endothelial cell regulates the adherence of monocytes and T cells to the endothelium. Two broad categories of leukocyte adhesion molecules exist (Table 30–1).[28] Members of the immunoglobulin superfamily include structures such as vascular cell adhesion molecule-1 (VCAM-1).[29–32] This adhesion molecule has particular interest in the context of early atherogenesis because it interacts with an integrin (very late antigen-4 [VLA-4]) characteristically expressed by only those classes of leukocytes that accumulate in nascent atheroma, monocytes, and T cells. Moreover, studies in rabbits and mice have shown expression of VCAM-1 on endothelial cells overlying very early atheromatous lesions.[30] Another member of the immunoglobulin superfamily of leukocyte adhesion molecules is intercellular adhesion molecule-1.[33, 34] This molecule is more promiscuous, both in the types of leukocytes it binds and because of its wide and constitutive expression at low levels by endothelial cells in many parts of the circulation.

Selectins constitute the other broad category of leukocyte adhesion molecules. The prototypical selectin, E-selectin (E for "endothelial," the cell type that selectively expresses this particular family member), probably has little to do with early atherogenesis. E-selectin preferentially recruits polymorphonuclear leukocytes, a cell type seldom found in early atheroma (but an essential protagonist in acute inflammation and host defenses against bacterial pathogens). Moreover, endothelial cells overlying atheroma do not express high levels of this adhesion molecule. Other members of this family, including P-selectin (P for "platelet," the original source of this adhesion molecule), may play a greater role in leukocyte recruitment in atheroma, because endothelial cells overlying human atheroma do express this adhesion molecule.[34–36] Selectins tend to promote saltatory or rolling locomotion of leukocytes over the endothelium. Adhesion molecules belonging to the immunoglobulin superfamily tend to promote tighter adhesive interactions and immobilization of leukocytes.[28]

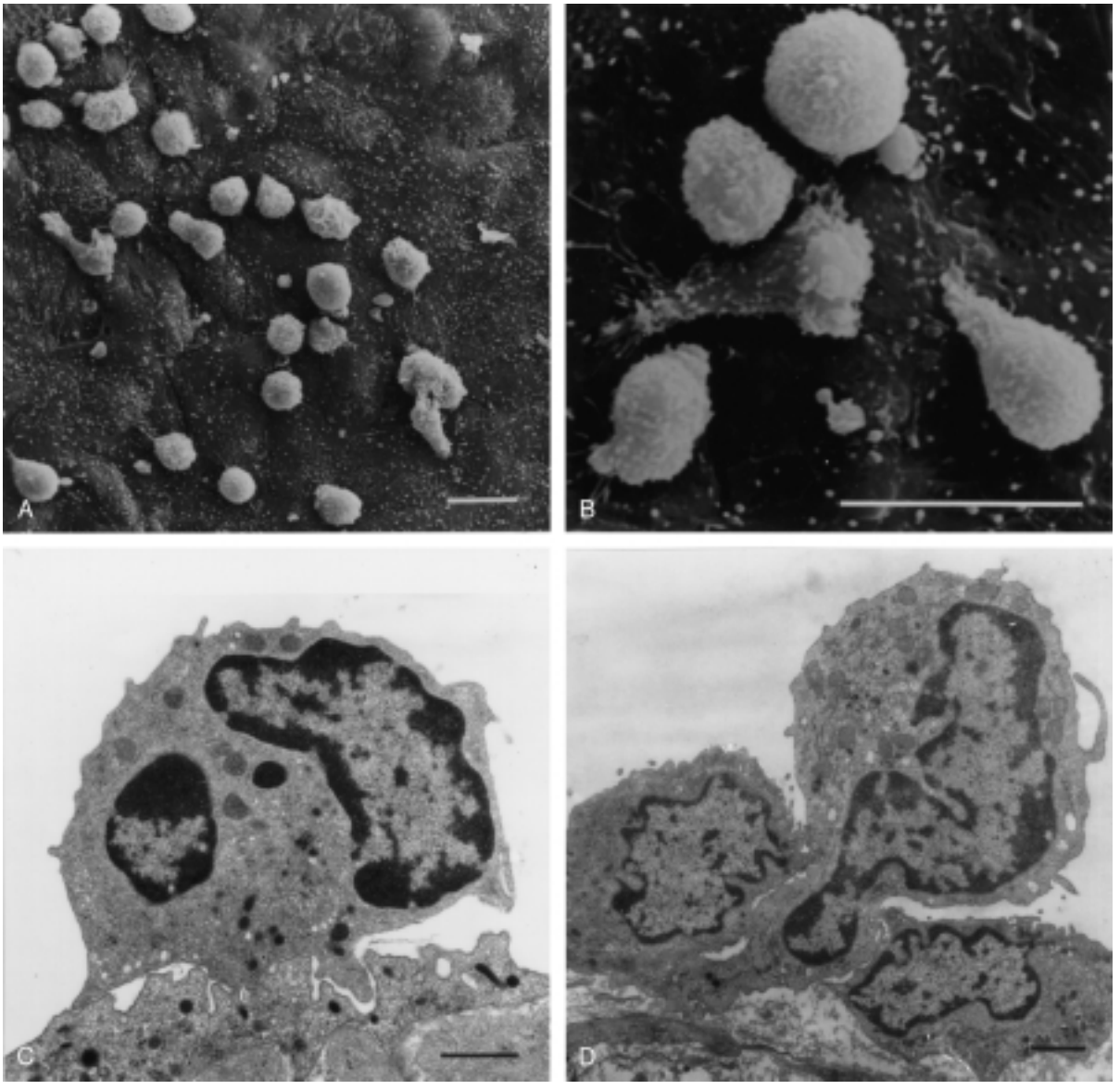

FIGURE 30–6. Electron microscopy of leukocyte interactions with the artery wall in hypercholesterolemic nonhuman primates. *A* and *B,* Scanning electron micrographs that demonstrate the adhesion of mononuclear phagocytes to the intact endothelium 12 days after initiating a hypercholesterolemic diet in rabbits. *C* and *D,* Transmission electron micrographs. Note the abundant interdigitations and intimate association of the monocyte with the endothelium in *C.* In *D,* a monocyte appears to diapedese between two endothelial cells to enter the intima. (From Faggiotto A, Ross R, Harker L: Studies of hypercholesterolemia in the nonhuman primate: I. Changes that lead to fatty streak formation. Arteriosclerosis 4:323–340, 1984.)

Once adherent to the endothelium, leukocytes must receive a signal to penetrate the endothelial and enter the arterial wall (see Figs. 30–4,*4* and 30–6*C*). The current concept of directed migration of leukocytes involves the action of protein molecules known as chemoattractant cytokines, or chemokines.[37] Two groups of chemokines have particular interest in recruiting the mononuclear cells characteristic of the early atheroma. One such molecule, known

TABLE 30–1. EXAMPLES OF ENDOTHELIAL-LEUKOCYTE ADHESION MOLECULES

NAME	ABBREVIATION	COGNATE LIGAND	LEUKOCYTES BOUND
Vascular cell adhesion molecule-1	VCAM-1	VLA-4 integrin	Monocytes Lymphocytes
Intercellular adhesion molecule-1	ICAM-1	CD11a integrin (LFA-1) CD11b integrin (Mac-1)	Many classes
E-selectin	Formerly ELAM-1	Sialyl-Lewis x	Granulocytes > monocytes > memory T cells
P-selectin	Formerly GMP-140	PSGL-1	Monocytes; lymphocytes; granulocytes
L-selectin		PSGL-1; mucosal vascular addressin (MAdCAM-1)	Expressed on the leukocytes

as monocyte chemoattractant protein-1 (MCP-1), is produced by the endothelium in response to oxidized lipoprotein and other stimuli. Cells intrinsic to the normal artery, including endothelium and smooth muscle, can produce this chemokine when stimulated by inflammatory mediators, as do many other cell types.[38, 39] MCP-1 selectively promotes the directed migration, or chemotaxis, of monocytes. Studies conducted with genetically modified mice lacking MCP-1 or its receptor CCR-2 have delayed and attenuated atheroma formation when placed on an atherosclerosis-prone, hyperlipidemic genetic background.[40, 41] Human atherosclerotic lesions express increased levels of MCP-1 compared with uninvolved vessels.[42] Thus, MCP-1 appears causally related to monocyte recruitment during atherogenesis in vivo. Another group of chemoattractant cytokines may heighten lymphocyte accumulation in plaques. Atheromas express a trio of lymphocyte-selective chemokines (interferon-inducible protein 10 [IP-10], interferon-inducible T-cell alpha chemoattractant [I-TAC], monokine induced by interferon-γ [MIG]).[43] Interferon gamma, a cytokine known to be present in atheromatous plaques, induces the genes encoding this family of T cell chemoattractants.

The Focality of Lesion Formation

The spatial heterogeneity of atherosclerosis has proven challenging to explain in mechanistic terms. Equal concentrations of blood-borne risk factors such as lipoproteins bathe the endothelium throughout the vasculature. It is difficult to envisage how injury due to inhaling cigarette smoke could produce any local rather than global effect on arteries. Yet, atheroma typically form focally, as revealed by studies of morphology, lipid accumulation, and adhesion molecule expression. Some have invoked a multicentric origin hypothesis of atherogenesis, positing that atheromas arise as benign leiomyomas of the artery wall.[44] The monotypia of various molecular markers such as glucose-6-phosphate dehydrogenase isoforms in individual atheroma supports this "monoclonal hypothesis" of atherogenesis.[45] However, the location of sites of lesion predilection at proximal portions of arteries after branch points or bifurcations at flow dividers suggests a hydrodynamic basis for early lesion development. Arteries without many branches (e.g., the internal mammary or radial arteries) tend not to develop atherosclerosis. (See also Chap. 41.)

Two concepts that can help understand how local flow disturbances might render certain foci sites of lesion predilection. Locally disturbed flow could induce alterations that promote the steps of early atherogenesis. Alternatively, the laminar flow that usually prevails at sites that do *not* tend to develop early lesions may elicit antiatherogenic homeostatic mechanisms (atheroprotective functions).[7] The endothelial cell experiences the laminar shear stress of normal flow and the disturbed flow (usually yielding decreased shear stress) at predilected sites. In vitro data suggest that laminar shear stress can augment the expression of genes that may protect against atherosclerosis, including forms of the enzymes superoxide dismutase or nitric oxide synthase.[46] Superoxide dismutase can reduce oxidative stress by catabolizing the reactive and injurious superoxide anion. Endothelial nitric oxide synthase produces the well-known endogenous vasodilator nitric oxide (•NO). However, beyond its vasodilating actions, •NO can resist inflammatory activation of endothelial functions such as expression of the adhesion molecule VCAM-1.[47] Nitric oxide appears to exert this antiinflammatory action at the level of gene expression by interfering with the transcriptional regulator nuclear factor kappa B (NFκB). Nitric oxide actually increases the production of an intracellular inhibitor (IκBα) of this important transcription factor.[48] The NFκB system regulates numerous genes involved in inflammatory responses in general, and in atherogenesis in particular.[49] These examples show how basic vascular biology is beginning to yield insight into previously obscure yet important aspects of atherogenesis. Future study of the molecular regulation of vascular cell function by mechanical stimuli promises to clarify further the mechanisms of lesion formation at particular sites in the circulation.

Likewise, study of vascular developmental biology may aid understanding of the tendency of certain arteries to develop atherosclerosis at different rates and in different ways. Smooth muscle cells vary in embryological origin in different regions.[50] For example, upper body arteries can recruit smooth muscle from neurectoderm, whereas in the lower body smooth muscle cells derive principally from mesoderm. Coronary artery smooth muscle cells arise from an Anlage known as the proepicardial organ.[51] How this heterogeneity in the origin of smooth muscle cells might impact human atherosclerosis and may help explain some of the poorly understood issues regarding dispersion of atheroma in time and space remains intriguing yet speculative. (See also Chap. 41.)

Intracellular Lipid Accumulation: Foam Cell Formation

The monocyte, once recruited to the arterial intima, can there imbibe lipid and become a foam cell, or lipid-laden macrophage (see Fig. 30–4,*5*). Whereas most cells can express the classical cell surface receptor for LDL, that receptor does not mediate foam cell formation. This is evident clinically, because patients lacking functional LDL receptors (familial hypercholesterolemia homozygotes) still develop tendinous xanthomas filled with foamy macrophages. The LDL receptor does not mediate foam cell formation because of its exquisite regulation by cholesterol. As soon as a cell collects enough cholesterol from LDL capture for its metabolic needs, an elegant transcriptional control mechanism quenches expression of the receptor (see also Chap. 31).

Instead of the classical LDL receptor, various molecules known as "scavenger" receptors appear to mediate the excessive lipid uptake characteristic of foam cell formation.[52, 53] The longest studied of these receptors belong to the scavenger receptor-A family. These surface molecules bind modified rather than native lipoproteins and apparently participate in their internalization. Atherosclerosis-prone mice with mutations that delete functional scavenger receptor-A have less exuberant fatty lesion formation than those with functional scavenger receptor-A molecules.[54] Other receptors that bind modified lipoprotein and that may participate in foam cell formation include CD36 and macrosialin, the latter exhibiting preferential binding specificity for oxidized forms of LDL (see Table 31–3).

Once macrophages have taken up residence in the intima and become foam cells, they not infrequently replicate. The factors that trigger macrophage cell division in the atherosclerotic plaque likely include macrophage colony-stimulating factor (M-CSF). This co-mitogen and survival factor for mononuclear phagocytes exists in human and experimental atheromatous lesions. Atherosclerosis-prone mice lacking functional M-CSF have retarded fatty lesion development.[55, 56] Other candidates for macrophage mitogens or co-mitogens include interleukin-3 and granulocyte-macrophage colony-stimulating factor.

Thus far, the scenario of the evolving atheroma has invoked only leukocytes, principally the macrophage. The precursor lesion, known as the fatty streak, consists mainly of accumulations of such lipid-engorged leukocytes. Fatty streaks may occur in children and in societies less affected by the atherosclerosis pandemic than the developed Western nations. Moreover, in experimental animals, withdrawal of the atherogenic diet or treatment with drugs that lower lipoprotein levels in plasma can reduce the extent of estab-

lished lesions. Thus, fatty streaks composed primarily of macrophages are likely reversible, at least to some extent.

THE EVOLUTION OF ATHEROMA

Smooth Muscle Cell Migration and Proliferation

Whereas the early events in atheroma initiation involve primarily altered endothelial function and recruitment and accumulation of leukocytes, the subsequent evolution of atheroma into more complex plaques involves smooth muscle cells as well (see Fig. 30–4,*6* and *7*).[57] Smooth muscle cells in the normal arterial tunica media differ considerably from those in the intima of an evolving atheroma. Although some smooth muscle cells likely arrive in the arterial intima early in life, others that accumulate in advancing atheroma likely arise from cells that have migrated from the underlying media into the intima.[11, 57] The chemoattractants for smooth muscle cells likely include molecules such as platelet-derived growth factor (PDGF), a potent smooth muscle cell chemoattractant secreted by activated macrophages and overexpressed in human atherosclerosis.[58] These smooth muscle cells in the atherosclerotic intima can also multiply by cell division. Estimated rates of division of smooth muscle cells in the human atherosclerotic lesion are on the order of less than 1 percent.[59] However, considerable smooth muscle cell accumulation may occur over the decades of lesion evolution.

Smooth muscle cells in the atherosclerotic intima appear to exhibit a less mature phenotype than the quiescent smooth muscle cells in the normal arterial medial layer. Instead of expressing primarily isoforms of smooth muscle myosin characteristic of adult smooth muscle cells, those in the intima have higher levels of the embryonic isoform of smooth muscle myosin.[60] Thus, smooth muscle cells in the intima seem to recapitulate an embryonic phenotype. These intimal smooth muscle cells in atheroma appear morphologically distinct as well. They contain more rough endoplasmic reticulum and fewer contractile fibers than do normal medial smooth muscle cells.

Although replication of smooth muscle cells in the steady state appears indolent in mature human atheroma, bursts of smooth muscle cell replication may occur during the life history of a given atheromatous lesion. For example, and as will be discussed in considerable detail later, episodes of plaque disruption with thrombosis may expose smooth muscle cells to potent mitogens, including the coagulation factor thrombin itself. Thus, accumulation of smooth muscle cells during atherosclerosis and growth of the intima may not occur in a continuous and linear fashion. Rather, "crises" may punctuate the history of an atheroma, during which bursts of smooth muscle replication and/or migration may occur (Fig. 30–7).

Smooth Muscle Cell Death During Atherogenesis

In addition to smooth muscle cell replication, death of these cells may also participate in complication of the atherosclerotic plaque (see Fig. 30–4,*8*). At least some smooth muscle cells in advanced human atheroma exhibit fragmentation of their nuclear DNA characteristic of programmed cell death, or apoptosis.[61–63] Apoptosis may occur in response to inflammatory cytokines known to be present in the evolving atheroma.[64] In addition to soluble cytokines that may trigger programmed cell death, the T cells in atheroma may participate in eliminating some smooth muscle cells. In particular, certain T cell populations known to accumulate in plaques can express *fas* ligand on their surface. *Fas* ligand can engage *fas* on the surface of smooth muscle cells and, in conjunction with soluble proinflammatory cytokines, lead to death of the smooth muscle cell.[65]

Thus, smooth muscle cell accumulation in the growing atherosclerotic plaque probably results from a tug-of-war between cell replication and cell death. Contemporary cell and molecular biological research has identified candidates

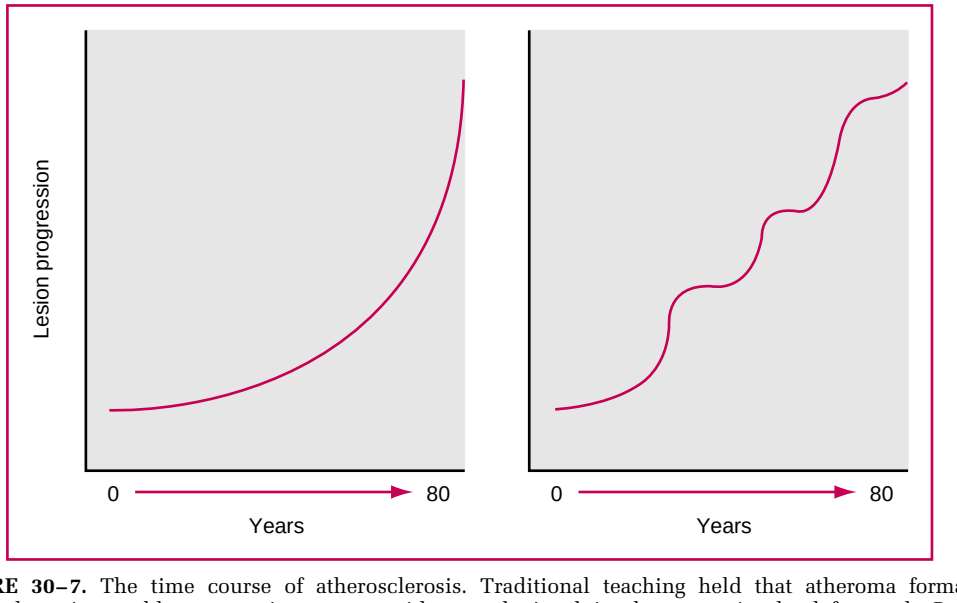

FIGURE 30–7. The time course of atherosclerosis. Traditional teaching held that atheroma formation followed an inexorably progressive course with age, depicted in the curve in the left panel. Current thinking suggests an alternative model, a step function rather than a monotonically upward course of lesion evolution in time (curve in right panel). According to this latter model, "crises" can punctuate periods of relative quiescence during the life history of a lesion. Such crises might follow an episode of plaque disruption, with mural thrombosis, and healing, yielding a spurt in smooth muscle proliferation and matrix deposition. Intraplaque hemorrhage due to rupture of a friable microvessel might produce a similar scenario. Such episodes might usually be clinically inapparent. Extravascular events such as an intercurrent infection with systemic cytokinemia or endotoxemia could elicit an "echo" at the level of the artery wall, evoking a round of local cytokine gene expression by "professional" inflammatory leukocytes resident in the lesion. The episodic model of plaque progression shown on the right fits human angiographic data better than the continuous function depicted on the left.

for mediating both the replication and attrition of smooth muscle cells, a concept that originated from the careful morphological observations of Virchow almost a century and a half ago.[3] Referring to the smooth muscle cells in the intima, Virchow noted that early atherogenesis involves a "multiplication of their nuclei." However, he recognized that cells in lesions can "hurry on to their own destruction" because of death of smooth muscle cells.

The Arterial Extracellular Matrix

Extracellular matrix rather than cells themselves makes up much of the volume of an advanced atherosclerotic plaque. Thus, extracellular constituents of plaque also require consideration. The major extracellular matrix macromolecules that accumulate in atheromas include interstitial collagens (types I and III) and proteoglycans such as versican, biglycan, aggrecan, and decorin.[10] Elastin fibers may also accumulate in atherosclerotic plaques. The vascular smooth muscle cell produces these matrix molecules in disease, just as it does during development and maintenance of the normal artery (see Fig. 30–4,*7*). Stimuli for excessive collagen production by smooth muscle cells include PDGF and transforming growth factor-beta (TGF-β), both constituents of platelet granules and products of many cell types found in lesions.[66]

Much like the accumulation of smooth muscle cells, extracellular matrix secretion also depends on a balance. In this case, the biosynthesis of the extracellular matrix molecules counters breakdown catalyzed in part by catabolic enzymes known as matrix metalloproteinases (MMPs).[67, 68] Dissolution of extracellular matrix macromolecules undoubtedly plays a role in migration of smooth muscle cells as they penetrate into the intima from the media through a dense extracellular matrix, traversing the elastin-rich internal elastic lamina. In injured arteries, overexpression of inhibitors of such proteinases (known as tissue inhibitors of metalloproteinases [TIMPs]) can delay smooth muscle accumulation in the intima.[69]

Extracellular matrix dissolution also likely plays a role in arterial remodeling that accompanies lesion growth. During the first part of the life history of an atheromatous lesion, growth of the plaque is outward, in an abluminal direction, rather than inward in a way that would lead to luminal stenosis[8, 9] (see Fig. 30–1). This outward growth of the intima leads to an increase in caliber of the entire artery. This so-called positive remodeling or compensatory enlargement must involve turnover of extracellular matrix molecules to accommodate the circumferential growth of the artery. Luminal stenosis tends to occur only after the plaque burden exceeds some 40 percent of the cross-sectional area of the artery.[8]

Angiogenesis in Plaques

The smooth muscle cell is not alone in its proliferation and migration within the evolving atherosclerotic plaque. Endothelial migration and replication also occur as plaques develop in microcirculation, characterized by plexuses of newly formed vessels.[70] Such plaque neovessels usually require special stains for visualization. However, histological examination with appropriate markers for endothelial cells reveals a rich neovascularization in evolving plaques. These microvessels likely form in response to angiogenic peptides overexpressed in atheroma. These angiogenesis factors include acidic and basic fibroblast growth factors (human BGFs I and II),[71] vascular endothelial growth factor (VEGF),[72, 73] and oncostatin M.[74]

These microvessels within plaques probably have considerable functional significance. For example, the abundant microvessels in plaques provide a relatively large surface area for the trafficking of leukocytes, which could include both entry and exit of leukocytes. Indeed, in the advanced human atherosclerotic plaque, microvascular endothelium displays the mononuclear-selective adhesion molecules such as VCAM-1 much more prominently than does the macrovascular endothelium overlying the plaque.[75] The microvascularization of plaques may also allow growth of the plaque overcoming diffusion limitations on oxygen and nutrient supply, in analogy with the concept of tumor angiogenic factors and growth of malignant lesions. Consistent with this view, administration of inhibitors of angiogenesis to mice with experimentally induced atheromas limits lesion expansion.[76] Finally, the plaque microvessels may be friable and prone to rupture like the neovessels in the diabetic retina. Hemorrhage and thrombosis in situ could promote a local round of smooth muscle cell proliferation and matrix accumulation in the area immediately adjacent to the microvascular disruption. This scenario illustrates a special case of one of the "crises" described earlier in the evolution of the atheromatous plaque (see Fig. 30–7). Attempts to augment myocardial perfusion by enhancing new vessel growth by transfer of angiogenic proteins or their genes might have adverse effects on lesion growth or clinical complications of atheroma by these mechanisms.

Plaque Mineralization

Plaques often develop areas of calcification as they evolve. Indeed, both Virchow and Rokitansky recognized morphological features of bone formation in atherosclerotic plaques in early microscopic descriptions of atherosclerosis.[3, 4] In recent years, understanding of the mechanism of mineralization during evolution of atherosclerotic plaques has advanced.[77] Some subpopulations of smooth muscle cells may foster calcification by enhanced secretion of cytokines such as bone morphogenetic proteins, homologues of TGF-β. Atheromatous plaques may also contain proteins with gamma carboxylated glutamic acid residues specialized in sequestering calcium and thus promoting mineralization.

COMPLICATIONS OF ATHEROSCLEROSIS

Arterial Stenoses and Their Clinical Implications

The process of initiation and evolution of the atherosclerotic plaque generally takes place over many years, during which the affected person often has no symptoms. After the plaque burden exceeds the capacity of the artery to remodel outward, encroachment on the arterial lumen begins. Eventually the stenoses may progress to a degree that impedes blood flow through the artery. Lesions that produce stenoses of greater than some 60 percent can cause flow limitations under conditions of increased demand. In the coronary tree such obstructive lesions may cause symptoms such as angina pectoris. Thus, the symptomatic phase of atherosclerosis usually occurs many decades after lesion initiation (see Fig. 30–1). The development of chronic stable angina pectoris or intermittent claudication on increased demand is a common presentation of this type of atherosclerotic disease. During this chronic asymptomatic or stable phase of lesion evolution, growth probably occurs discontinuously, with periods of relative quiescence punctuated by episodes of rapid progression (see Fig. 30–7). Human angiographic studies support this discontinuous growth of coronary artery stenoses.[78, 79]

However, in many cases of myocardial infarction no history of prior stable angina heralds the acute event. In some cases, this mode of transition from the chronic stable or asymptomatic phase of coronary atherosclerosis may result from progressive intimal growth and critical narrowing of the vessel due to a high-grade stenosis. Several kinds of clinical observation over the last several years, however, suggest that most myocardial infarctions result not from

critical blockages but from lesions that produce stenoses that do not limit flow. For example, in individuals who have undergone coronary arteriography in the months preceding myocardial infarction, the culprit lesion most often shows less than 50 percent stenosis. In a compilation of four such serial angiographic studies, only approximately 15 percent of acute myocardial infarctions arose from lesions with degrees of stenosis greater than 60 percent on an antecedent angiogram.[80, 81]

Instead of progressive growth of the intimal lesion to a critical stenosis, we now recognize that thrombosis, complicating a not necessarily occlusive plaque, most often causes episodes of unstable angina or acute myocardial infarction. Angiographic studies performed in individuals undergoing thrombolysis support this view. In one such study, almost half of patients undergoing thrombolysis for a first myocardial infarction had an underlying stenosis of less than 50 percent once the acute thrombus was lysed.[82]

It is a misconception, however, that small atheromas cause most myocardial infarction. Indeed, culprit lesions of acute myocardial infarction actually may be sizable. However, they may not produce a critical luminal narrowing because of the phenomenon of compensatory enlargement. Studies using intravascular ultrasonography, a cross-sectional imaging modality, to examine culprit lesions of acute myocardial infarction support this concept[83] (see also Chap. 12). Of course, critical stenoses do cause myocardial infarctions. In fact, the high-grade stenoses are more likely to cause acute myocardial infarction than nonocclusive lesions.[80] However, because the noncritical stenoses by far outnumber the tight focal lesions in a given coronary tree, the lesser stenoses cause more infarctions even though their individual probability of causing a myocardial infarction is less than that of the high-grade stenoses.

Thrombosis and Atheroma Complication

This evolution in our view of the pathogenesis of the acute coronary syndromes places new emphasis on thrombosis as the critical mechanism of transition from chronic to acute atherosclerosis. In the past decade we have seen considerable progress in our understanding of the mechanisms of coronary thrombosis. We now appreciate that a physical disruption of the atherosclerotic plaque commonly causes acute thrombosis.[68, 80, 84] Two major modes of plaque disruption provoke most coronary thrombi. The first mechanism, accounting for some two thirds of acute myocardial infarctions, involves a fracture of the plaque's fibrous cap (Fig. 30–8*A*).[80] The second mode involves a superficial erosion of the intima (see Fig. 30–8*B*), accounting for up to a fourth of acute myocardial infarctions in highly selected referral cases from medical examiners who have studied individuals who succumbed to sudden cardiac death.[85] Superficial erosion appears more frequently in women than in men as a mechanism of coronary sudden death.[86, 87]

Plaque Rupture and Thrombosis

The rupture of the plaque's fibrous cap probably reflects an imbalance between the forces that impinge on the plaque's cap and the mechanical strength of the fibrous cap.[88] Interstitial forms of collagen provide most of the biomechanical resistance to disruption to the fibrous cap. Hence, the metabolism of collagen probably participates in regulating the propensity of a plaque to rupture. Factors that decrease collagen synthesis by smooth muscle cells can impair their ability to repair and maintain the plaque's fibrous cap. For example, the T cell–derived cytokine interferon gamma potently inhibits smooth muscle cell collagen synthesis (Fig. 30–9).[66] On the other hand, as already noted, certain mediators released from degranulating platelets can increase smooth muscle cell collagen synthesis, tending to reinforce the plaque's fibrous structure. Such mediators include TGF-β and PDGF contained in platelet granules.[66]

FIGURE 30–8. See color plate 19.

FIGURE 30–9. See color plate 19.

In addition to reduced de novo collagen synthesis by smooth muscle cells, increased catabolism of the extracellular matrix macromolecules that comprise the fibrous cap can also contribute to weakening this structure and rendering it susceptible to rupture, and hence thrombosis. The same matrix-degrading enzymes thought to contribute to smooth muscle migration and arterial remodeling may contribute to weakening of the fibrous cap as well (see Fig. 30–9).[67, 68] Macrophages in advanced human atheromas overexpress matrix metalloproteinases and elastolytic cathepsins that can break down the collagen and elastin of the arterial extracellular matrix.[89–91] Thus, the strength of the plaque's fibrous cap is under dynamic regulation, linking the inflammatory response in the intima with the molecular determinants of plaque stability and, hence, the thrombotic complications of atheroma. The thinning of the plaque's fibrous cap, a result of reduced collagen synthesis and increased degradation, probably explains why pathological studies have shown that a thin fibrous cap characterizes atherosclerotic plaques that have ruptured and caused fatal myocardial infarction.[92, 93]

Another feature of the so-called vulnerable atherosclerotic plaque defined by pathological analysis is a relative lack of smooth muscle cells.[94] As explained earlier, inflammatory mediators both soluble and associated with the surface of T lymphocytes can provoke programmed cell death of smooth muscle cells. "Dropout" of smooth muscle cells from regions of local inflammation within plaques probably contributes to the relative lack of smooth muscle cells at places where plaques rupture.[63] Because these cells are the source of the newly synthesized collagen needed to repair and maintain the matrix of the fibrous cap, the lack of smooth muscle cells may contribute to weakening of the fibrous cap and, hence, the propensity of that plaque to rupture.[68]

A prominent accumulation of macrophages and a large lipid pool is a third microanatomical feature of the so-called vulnerable atherosclerotic plaque.[94] From a strictly biomechanical viewpoint, a large lipid pool can serve to concentrate biomechanical forces on the shoulder regions of plaques, which are common sites of rupture of the fibrous cap.[95, 96] From a metabolic standpoint, the activated macrophage characteristic of the plaque's core region produces the proinflammatory cytokines and the matrix-degrading enzymes thought to regulate aspects of matrix catabolism and smooth muscle cell apoptosis in turn.[97] The success of lipid-lowering therapy in reducing the incidence of acute myocardial infarction or unstable angina in patients at risk may result from a reduced accumulation of lipid and decrease in inflammation. Recent animal studies and monitoring of peripheral markers of inflammation in humans support this concept.[98–101] (See also Chap. 31.)

Thrombosis Due to Superficial Erosion of Plaques

The foregoing section discusses the pathophysiology of rupture of the plaque's fibrous cap. The pathobiology of superficial erosion is much less well understood. In experimental atherosclerosis in the nonhuman primate areas of endothelial loss and platelet deposition occur in the more advanced plaques (Fig. 30–10). In humans, superficial erosion ap-

pears more likely to cause fatal acute myocardial infarction in women and in individuals with hypertriglyceridemia and diabetes mellitus.[85–87] However, the underlying molecular mechanisms remain obscure. Apoptosis of endothelial cells could contribute to desquamation of endothelial cells in areas of superficial erosion. Likewise, matrix metalloproteinases such as certain gelatinases specialized in degrading the nonfibrillar collagen found in the basement membrane (e.g., collagen type IV) might also sever the tetherings of the endothelial cell to the subjacent basal lamina and promote their desquamation.

Most plaque disruptions do not give rise to clinically apparent coronary events. Careful pathoanatomical examination of hearts obtained from individuals who have succumbed to noncardiac death have shown a surprisingly high incidence of focal plaque disruptions with limited mural thrombi. Moreover, hearts fixed immediately after explantation from individuals with severe but chronic stable coronary atherosclerosis and who had undergone transplantation for ischemic cardiomyopathy show similarly evidence for ongoing but asymptomatic plaque disruption.[84] Experimentally, in atherosclerotic nonhuman primates, mu-

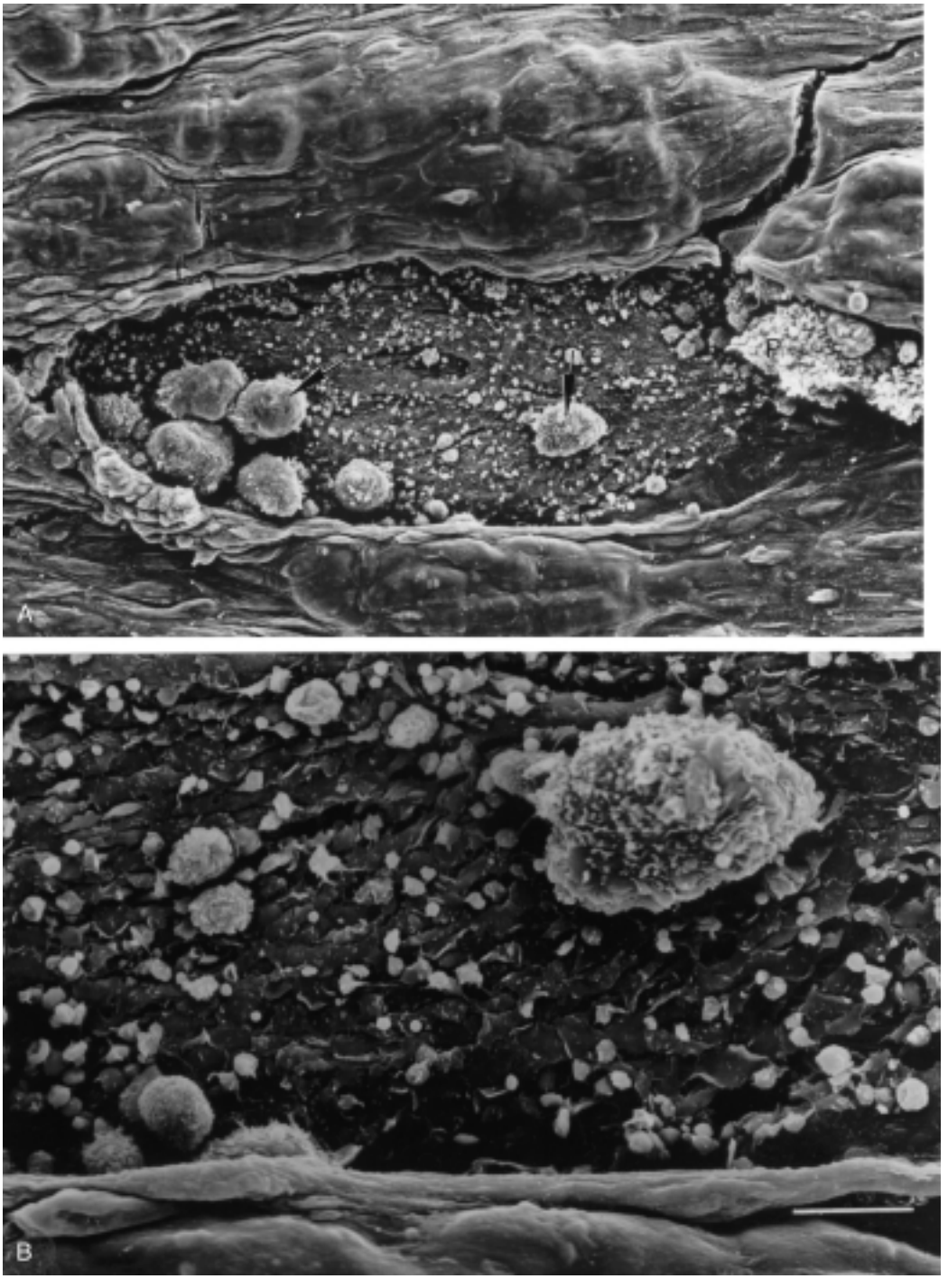

FIGURE 30–10. Superficial erosion of experimental atherosclerotic lesions shown by scanning electron microscopy. *A,* In the low-power view, the rent in endothelium is evident. Leukocytes have adhered to the subendothelium, which is beginning to be covered with a carpet of platelets. *B,* The high-power view shows a field selected from the center of *A* that shows the leukocytes and platelets adherent to the subendothelium. (From Faggiotto A, Ross R: Studies of hypercholesterolemia in the nonhuman primate: II. Fatty streak conversion to fibrous plaque. Arteriosclerosis 4:341–356, 1984.)

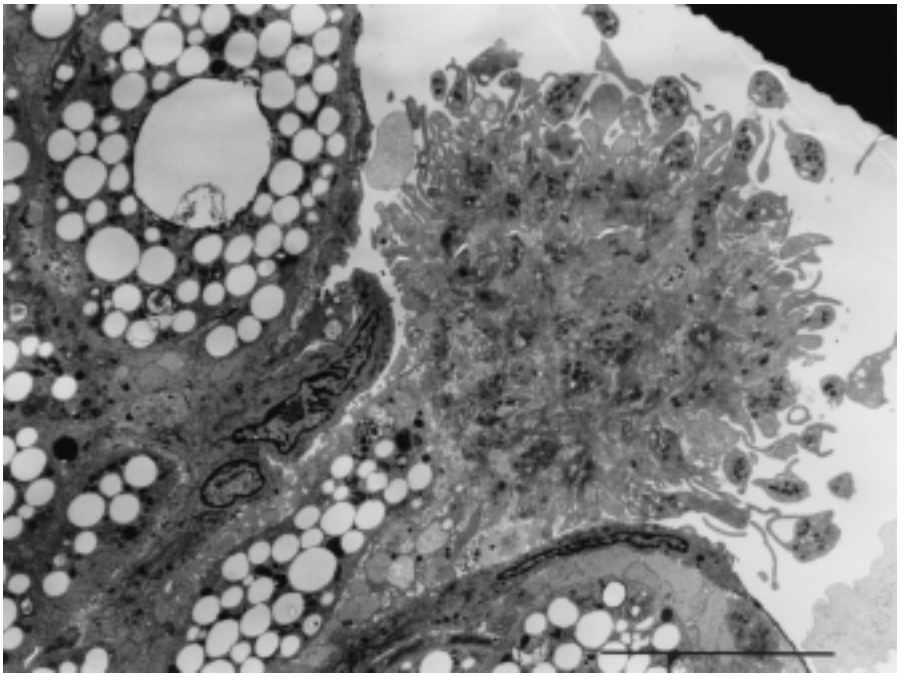

FIGURE 30–11. Platelet thrombus complicating a plaque disruption in experimental atherosclerosis. This transmission electron micrograph shows a cross section of macrophage studded with platelets that have clumped to form a microscopic thrombus. (From Faggiotto A, Ross R, Harker L: Studies of hypercholesterolemia in the nonhuman primate: I. Changes that lead to fatty streak formation. Arteriosclerosis 4:323-340, 1984.)

ral platelet thrombi can complicate plaque erosions without causing arterial occlusion (Fig. 30–11).[102] Therefore, repetitive cycles of plaque disruption, thrombosis in situ, and healing probably contribute to lesion evolution and plaque growth. Such episodes of thrombosis and healing constitute one type of "crisis" in the history of a plaque that may cause a burst of smooth muscle cell proliferation, migration, and matrix synthesis. The TGF-β and PDGF released from platelet granules stimulate collagen synthesis by smooth muscle cells.[66] Thrombin, generated at sites of mural thrombosis, potently stimulates smooth muscle cell proliferation.[103] The late stage or "burned out" fibrous and calcific atheroma may represent a late stage of a plaque previously rich in lipid and vulnerable but now rendered fibrous and hypocellular owing to a wound-healing response mediated by the products of thrombosis.

SPECIAL CASES OF ARTERIOSCLEROSIS

Restenosis after Arterial Intervention

(See also Chap. 38)

The problem of restenosis after percutaneous arterial intervention represents a special case of arteriosclerosis. After balloon angioplasty, luminal narrowing recurs in approximately one third of cases within 6 months (see also Chap. 38). Initially, work on the pathophysiology of restenosis after angioplasty focused on smooth muscle proliferation.[104] A good deal of the thinking regarding the pathobiology of restenosis depended on extension to the human situation of the results of withdrawal of an overinflated balloon in a previously normal rat carotid artery. Study of this very well standardized preparation promoted precise understanding of the kinetics of intimal thickening after this type of injury. Furthermore, these studies identified a role for PDGF in stimulating smooth muscle cell migration and basic fibroblast growth factor in triggering smooth muscle cell proliferation in the rat carotid artery after injury.[105–107] However, the attempts to transfer this information to human restenosis met with considerable frustration. This disparity between the balloon withdrawal injury of animals arteries and human restenosis is not surprising. The substrate of the animal studies was usually a normal rather than atherosclerotic artery, with all the attendant cellular and molecular differences highlighted earlier. Moreover, a high-pressure inflation of an angioplasty balloon only vaguely resembles the overinflated balloon withdrawal injury commonly practiced in rats.

Although smooth muscle cell proliferation appears prominent in the simple experimental models of intimal thickening, observations on human specimens showed relatively low rates of smooth muscle cell proliferation and called into question therapeutic targeting of this process. Moreover, intravascular ultrasound studies in humans, and considerable evidence from animal experimentation, suggested that a substantial proportion of the loss of luminal caliber after balloon angioplasty resulted from a constriction of the vessel from the adventitial side ("negative remodeling").[108] These observations renewed interest in adventitial inflammation with scar formation and wound contraction as a mechanism of arterial constriction after balloon angioplasty.[109, 110]

The widespread introduction of stents has changed the face of the restenosis problem. The process of in-stent stenosis, in contrast to restenosis after balloon angioplasty, depends uniquely on intimal thickening, as opposed to "negative remodeling." The stent provides a firm scaffold that prevents constriction from the adventitia. Histological analyses reveal that a great deal of the volume of the in-stent restenotic lesion is made up of "myxomatous" tissue, comprising occasional stellate smooth muscle cells embedded in a loose and highly hydrated extracellular matrix.

The introduction of stents has reduced the clinical impact of restenosis because of the very effective increase in luminal diameter achieved by this technique. Even if a considerable degree of lumen loss occurs due to intimal thickening, the luminal caliber remains sufficient to alleviate the patient's symptoms because of the excellent dilatation achieved. Currently, radiation treatment, presumably targeting smooth muscle proliferation and matrix synthesis, is under evaluation as a therapeutic approach to limiting in-stent stenosis (see Chap. 38).

Accelerated Arteriosclerosis after Transplantation (See also Chap. 20)

Since the advent of effective immunosuppressive therapy such as cyclosporine, the major limitation to long-term sur-

vival of cardiac allografts is the development of an accelerated form of arterial hyperplastic disease (see also Chap. 20). I favor the term *arteriosclerosis* (hardening of the arteries) rather than *atherosclerosis* (gruel-hardening) to describe this process because of the inconstant association with lipids (the "gruel" in atherosclerosis).[111] This form of arterial disease often presents a diagnostic challenge. The patient may not experience typical anginal symptoms due to the interruption of cardiac denervation after transplantation. In addition, graft coronary disease is concentric and diffuse, not only affecting the proximal epicardial coronary vessels but also penetrating smaller intramyocardial branches (Fig. 30–12).[112] For this reason, the angiogram, well suited to visualize focal and eccentric stenoses, consistently underestimates the degree of transplantation arteriosclerosis.[113]

FIGURE 30–12. See color plate 20.

In most centers, a majority of patients undergoing transplantation have atherosclerotic disease and ischemic cardiomyopathy. However, a sizable minority undergo heart transplantation for idiopathic dilated cardiomyopathy and may have few risk factors for atherosclerosis. Even in the absence of traditional risk factors, this latter group of individuals shares the risk of developing accelerated arteriosclerosis. This observation suggests that the pathophysiology of this form of accelerated arteriosclerosis differs from that of usual atherosclerosis.

The selective involvement of the engrafted vessels with sparing of the host's native arteries suggests that accelerated arteriopathy does not merely result from the immunosuppressive therapy or other systemic factors in the transplantation recipient. Rather, these observations suggest that the immunological differences between the host and the recipient vessels might contribute to the pathogenesis of this disease. Considerable evidence from both human and experimental studies currently supports this viewpoint. Endothelial cells in the transplanted coronary arteries express histocompatibility antigens that can engender an allogeneic immune response from host T cells.[114] The activated T cells can secrete cytokines (e.g., interferon gamma) that can augment histocompatibility gene expression, recruit leukocytes by induction of adhesion molecules, and activate macrophages to produce smooth muscle cell chemoattractants and growth factors. Interruption of interferon gamma signaling can prevent experimental graft coronary disease in mice.[115] This disease appears to occur despite cyclosporine therapy, because this immunosuppressant is relatively ineffective as a suppressor of the endothelial allogeneic response. These observations hold out the hope that combinations of cyclosporine with other immunosuppressive agents that more effectively suppress the endothelial allogeneic response may prove an effective therapy to retard or prevent graft arteriosclerosis.

The data just summarized suggest that graft arteriosclerosis represents an extreme case of immunologically driven arterial hyperplasia (Fig. 30–13) that can happen in the absence of other risk factors.[111] On the other extreme, patients with homozygous familial hypercholesterolemia can develop fatal atherosclerosis in the first decade of life due solely to an elevation in LDL. The vast majority of patients with atherosclerosis fall somewhere between these two extremes. Analysis of usual atherosclerotic lesions shows evidence for a chronic immune response and lipid accumulation. Therefore, by studying the extreme cases, such as transplantation arteriopathy and familial hypercholesterolemia, one can gain insight into elements of the pathophysiology that contribute to the multifactorial form of atherosclerosis that affects the majority of patients.

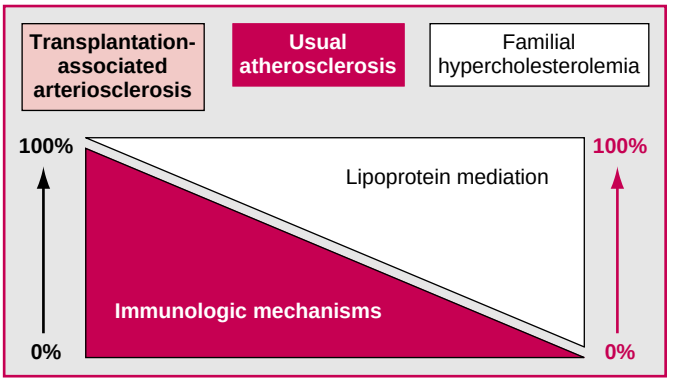

FIGURE 30–13. A multifactorial view of the pathogenesis of atherosclerosis. This diagram depicts two extreme cases of atherosclerosis. One *(far left side)* represents accelerated arteriosclerosis that can occur in the transplanted heart in the absence of traditional coronary risk factors. This disease likely represents primarily immune-mediated arterial intimal disease. The other extreme *(far right side)* depicts the case of a child who may succumb to rampant atherosclerosis in the first decade of life due solely to an elevated low density lipoprotein (LDL) caused by a mutation in the LDL receptor (homozygous familial hypercholesterolemia). Between these two extremes lie the vast majority of patients with atherosclerosis, probably involving various mixtures of immune and inflammatory and/or lipoprotein-mediated disease. One can further consider that this diagram extends to a third dimension that would involve other candidate risk factors such as homocysteine, lipoprotein(a), infection, tobacco abuse, and so on.

Aneurysmal Disease (See also Chap. 40)

Atherosclerosis produces not only stenoses but also aneurysmal disease. Why does a single disease process manifest itself in directionally opposite manner, for example, most commonly producing stenoses in the coronary arteries but causing ectasia of the abdominal aorta? In particular, aneurysmal disease characteristically affects the infrarenal abdominal aorta. This region is highly prone to the development of atherosclerosis. Data from the Pathobiological Determinants of Atherosclerosis In Youth Study (PDAY) show that the dorsal surface of the infrarenal abdominal aorta has a particular predilection for development of fatty streaks and raised lesions in Americans younger than age 35 who succumbed for noncardiac reasons.[116–118] Because of the absence of vasa vasorum the relative lack of blood supply to the tunica media in this portion of the abdominal aorta might explain the regional susceptibility of this portion of the arterial tree to aneurysm formation. In addition, the lumbar lordosis of the biped human may alter the hydrodynamics of blood flow in the distal aorta, yielding flow disturbances that may promote lesion formation.

Histological examination shows considerable distinction between occlusive atherosclerotic disease and aneurysmal disease. In typical coronary artery atherosclerosis, expansion of the intimal lesion produces stenotic lesions. The tunica media underlying the expanded intima is often thinned, but its general structure remains relatively well preserved. In contrast, transmural destruction of the arterial architecture occurs in aneurysmal disease. In particular, the usually well-defined laminar structure of the normal tunica media disappears with loss of the elastic laminae. The medial smooth muscle cells, usually well preserved in typical stenotic lesions, are notable for their paucity in the media of advanced aortic aneurysms.

Study of the pathophysiology that underlies these anatomical pathological findings has proven frustrating. Informative animal models are not available. The human specimens obtainable for analysis generally represent the late stages of this disease. Nonetheless, recent work has

identified several mechanisms that may underlie the peculiar pathology of aneurysmal disease. Widespread destruction of the elastic laminae suggests a role for degradation of elastin, collagen, and other constituents of the arterial extracellular matrix. Many studies have documented overexpression of matrix-degrading proteinases including matrix metalloproteinases in human aortic aneurysm specimens.[119–121]

Thus, heightened elastolysis may explain the breakdown of the usually ordered structure of the tunica media in this disease. In addition, aortic aneurysms show evidence for considerable inflammation, particularly in the adventitia.[122] The lymphocytes that characteristically abound on the adventitial side of aneurysmal tissue suggest that apoptosis of smooth muscle cells triggered by inflammatory mediators including soluble cytokines and *fas* ligand, elaborated by these inflammatory cells, may contribute to smooth muscle cell destruction, and promote aneurysm formation.[123] Although extracellular matrix degradation and smooth muscle cell death also occur in sites where atherosclerosis causes stenosis, they appear to predominate in regions of aneurysm formation and to affect the tunica media much more extensively, for reasons that remain obscure.

Infection and Atherosclerosis

Recently, interest has increased in the possibility that infections may cause atherosclerosis. A considerable body of seroepidemiological evidence supports a role for certain bacteria, notably *Chlamydia pneumoniae*, and certain viruses, notably *cytomegalovirus* (CMV), in the etiology of atherosclerosis.[124, 125] The seroepidemiological studies have spurred a number of in vivo and in vitro experiments that lend varying degrees of support to this concept. In evaluation of the seroepidemiological evidence, several caveats apply. First, confounding factors should be carefully considered.[126] For example, smokers may have a higher incidence of bronchitis due to *C. pneumoniae*. Therefore, evidence for infection with *C. pneumoniae* may merely serve as a marker for tobacco use, a known risk factor for atherosclerotic events. Additionally, a strong bias favors publication of positive studies as opposed to negative studies. Thus, meta-analyses of seroepidemiological studies may be slanted toward the positive merely because of underreporting of negative studies. Finally, atherosclerosis is a common and virtually ubiquitous disease in developed countries. In most societies, many adults have serological evidence of prior infections with Herpesviridae, such as CMV, and respiratory pathogens, such as *C. pneumoniae*. It is difficult to sort out coincidence from causality when the majority of the population studied has evidence of both infection and atherosclerosis. (See also Chap. 31.)

Although proof that bacteria or viruses can cause atherosclerosis remains elusive, it is quite plausible that infections may potentiate the action of traditional risk factors, such as hypercholesterolemia. Based on the vascular biology of atherosclerosis discussed in this chapter, a number of scenarios might apply. First, cells within the atheroma itself may be a site for infection. For example, macrophages existing in an established atherosclerotic lesion might become infected with *C. pneumoniae*, which could spur their activation and accelerate the inflammatory pathways that are currently believed to operate within the atherosclerotic intima. Specific microbial products such as lipopolysaccharides, heat-shock proteins, or other virulence factors might act locally at the level of the artery wall to potentiate atherosclerosis in infected lesions.[127–133]

Extravascular infection might also influence the development of atheromatous lesions and provoke their complication. For example, circulating endotoxin or cytokines produced in response to a remote infection can act locally at the level of the artery wall to promote the activation of vascular cells and of leukocytes in preexisting lesions, producing an "echo" at the level of the artery wall of a remote infection.[134] Also, the acute phase response to an infection in a nonvascular site might affect the incidence of thrombotic complications of atherosclerosis by increasing fibrinogen or plasminogen activator inhibitor-1 (PAI-1) or otherwise altering the balance between coagulation and fibrinolysis. Such disturbance in the prevailing prothrombotic, fibrinolytic balance may critically influence whether a given plaque disruption will produce a clinically inapparent transient or nonocclusive thrombus or sustained and occlusive thrombi that could cause an acute coronary event.

Acute infections might also produce hemodynamic alterations that could trigger coronary events. For example, the tachycardia and increased metabolic demands of fever could augment the oxygen requirements of the heart, precipitating ischemia in an otherwise compensated individual. These various scenarios illustrate how infectious processes, either local in the atheroma or extravascular, might aggravate atherogenesis, particularly in preexisting lesions or in concert with traditional risk factors. Currently, a number of well-designed trials are critically testing the hypothesis that treatment with antibiotics can reduce recurrent coronary events in survivors of myocardial infarction. The results of such studies will be forthcoming in the next several years. However, even if these studies were positive, they would not establish a role for a particular infectious agent, nor could they prove that the antibiotic effect of the agents tested, rather than some other action not related to their antimicrobial effect, could produce benefit.

Acknowledgment

This chapter is dedicated to the memory of Dr. Russell Ross, author of the chapter on atherosclerosis in the last three editions of this text. Dr. Ross died unexpectedly in March of 1999 and was thus unable to participate in authoring this chapter, as had been planned.

REFERENCES

1. Leibowitz J: The History of Coronary Heart Disease. Berkeley, University of California Press, 1970.
2. Osler W: The Principles and Practice of Medicine. Baltimore, Appleton, 1892.
3. Virchow R: Cellular Pathology. London, John Churchill, 1858.
4. Rokitansky K: The Organs of Circulation: A Manual of Pathological Anatomy. Vol IV. Philadelphia, Blanchard & Lea, 1855.
5. Anitschkow N, Chalatow S: On experimental cholesterin steatosis and its significance in the origin of some pathological processes (1913). Reprinted in Arteriosclerosis 3:178–182, 1983.
6. Tuzcu EM, Hobbs RE, Rincon G, et al: Occult and frequent transmission of atherosclerotic coronary disease with cardiac transplantation: Insights from intravascular ultrasound. Circulation 91:1706–1713, 1995.
7. Gimbrone MA Jr, Resnick N, Nagel T, et al: Hemodynamics, endothelial gene expression, and atherogenesis. Ann N Y Acad Sci 811:1–10, discussion 811:10–11, 1997.

7a. McGill HC Jr, McMahan CA, Zieske AW, et al: Association of coronary heart disease risk factors with microscopic qualities of coronary atherosclerosis in youth. Circulation 102:374–379, 2000.

7b. Stamler J, Daviglus ML, Garside DB, et al: Relationship of baseline serum cholesterol levels in 3 large cohorts of younger men to long-term coronary, cardiovascular, and all-cause mortality and to longevity. JAMA 284:311–318, 2000.

8. Glagov S, Weisenberg E, Zarins C, et al: Compensatory enlargement of human atherosclerotic coronary arteries. N Engl J Med 316:371–375, 1987.
9. Clarkson TB, Prichard RW, Morgan TM, et al: Remodeling of coronary arteries in human and nonhuman primates. JAMA 271:289–294, 1994.
10. Wight TN: The extracellular matrix and atherosclerosis. Curr Opin Lipidol 6:326–334, 1995.
11. Schwartz SM, deBlois D, O'Brien ER: The intima: Soil for atherosclerosis and restenosis. Circ Res 77:445–465, 1995.
12. Gordon D, Schwartz SM: Replication of arterial smooth muscle cells in hypertension and atherosclerosis. Am J Cardiol 59:44A–48A, 1987.

INITIATION OF ATHEROSCLEROSIS

13. Kruth HS: The fate of lipoprotein cholesterol entering the arterial wall. Curr Opin Lipidol 8:246–252, 1997.

14. Nievelstein PF, Fogelman AM, Mottino G, et al: Lipid accumulation in rabbit aortic intima 2 hours after bolus infusion of low density lipoprotein: A deep-etch and immunolocalization study of ultrarapidly frozen tissue. Arterioscler Thromb 11:1795–1805, 1991.
15. Camejo G, Hurt-Camejo E, Wiklund O, et al: Association of apo B lipoproteins with arterial proteoglycans: Pathological significance and molecular basis. Atherosclerosis 139:205–222, 1998.
16. Schwenke DC, Carew TE: Initiation of atherosclerotic lesions in cholesterol-fed rabbits: I. Focal increases in arterial LDL concentration precede development of fatty streak lesions. Arteriosclerosis 9:895–907, 1989.
17. Schwenke DC, Carew TE: Initiation of atherosclerotic lesions in cholesterol-fed rabbits: II. Selective retention of LDL vs. selective increases in LDL permeability in susceptible sites of arteries. Arteriosclerosis 9:908–918, 1989.
18. Williams KJ, Tabas I: The response-to-retention hypothesis of atherogenesis reinforced. Curr Opin Lipidol 9:471–474, 1998.
19. Witztum JL, Berliner JA: Oxidized phospholipids and isoprostanes in atherosclerosis. Curr Opin Lipidol 9:441–448, 1998.
20. Rong JX, Rangaswamy S, Shen L, et al: Arterial injury by cholesterol oxidation products causes endothelial dysfunction and arterial wall cholesterol accumulation. Arterioscler Thromb Vasc Biol 18:1885–1894, 1998.
21. Tabas I: Nonoxidative modifications of lipoproteins in atherogenesis. Ann Rev Nutr 19:123–139, 1999.
22. Herrmann RA, Malinauskas RA, Truskey GA: Characterization of sites with elevated LDL permeability at intercostal, celiac, and iliac branches of the normal rabbit aorta. Arterioscler Thromb 14:313–323, 1994.
23. Ushio-Fukai M, Alexander RW, Akers M, et al: p38 Mitogen-activated protein kinase is a critical component of the redox-sensitive signaling pathways activated by angiotensin II: Role in vascular smooth muscle cell hypertrophy. J Biol Chem 273:15022–15029, 1998.
24. Cyrus T, Witztum JL, Rader DJ, et al: Disruption of the 12/15-lipoxygenase gene diminishes atherosclerosis in apo E-deficient mice. J Clin Invest 103:1597–1604, 1999.
25. Gimbrone M Jr, Cybulsky MI, Kume N, et al: Vascular endothelium: An integrator of pathophysiological stimuli in atherogenesis. Ann N Y Acad Sci 748:122–131, 1995.
26. Emeson EE, Robertson AL Jr: T lymphocytes in aortic and coronary intimas. Am J Pathol 130:369–376, 1988.
27. Hansson G, Libby P: The role of the lymphocyte. *In* Fuster V, Ross R, Topol E (eds): Atherosclerosis and Coronary Artery Disease. Vol 1. New York, Lippincott-Raven, 1996.
28. Frenette P, Wagner D: Adhesion molecules. N Engl J Med 334:1526–1529, 1996.
29. Cybulsky MI, Gimbrone MA Jr: Endothelial expression of a mononuclear leukocyte adhesion molecule during atherogenesis. Science 251: 788–791, 1991.
30. Li H, Cybulsky MI, Gimbrone MA Jr, et al: An atherogenic diet rapidly induces VCAM-1, a cytokine regulatable mononuclear leukocyte adhesion molecule, in rabbit endothelium. Arterioscler Thromb 13:197–204, 1993.
31. Nakashima Y, Raines EW, Plump AS, et al: Upregulation of VCAM-1 and ICAM-1 at atherosclerosis-prone sites on the endothelium in the apoE-deficient mouse. Arterioscler Thromb Vasc Biol 18:842–851, 1998.
32. Iiyama K, Hajra L, Iiyama M, et al: Patterns of vascular cell adhesion molecule-1 and intercellular adhesion molecule-1 expression in rabbit and mouse atherosclerotic lesions and at sites predisposed to lesion formation. Circ Res 85:199–207, 1999.
33. Poston RN, Haskard DO, Coucher JR, et al: Expression of intercellular adhesion molecule-1 in atherosclerotic plaques. Am J Pathol 140:665–673, 1992.
34. Davies MJ, Gordon JL, Gearing AJ, et al: The expression of the adhesion molecules ICAM-1, VCAM-1, PECAM, and E-selectin in human atherosclerosis. J Pathol 171:223–229, 1993.
35. Vora DK, Fang ZT, Liva SM, et al: Induction of P-selectin by oxidized lipoproteins: Separate effects on synthesis and surface expression. Circ Res 80:810–818, 1997.
36. Dong ZM, Chapman SM, Brown AA, et al: The combined role of P- and E-selectins in atherosclerosis. J Clin Invest 102:145–152, 1998.
37. Luster AD: Chemokines—chemotactic cytokines that mediate inflammation. N Engl J Med 338:436–445, 1998.
38. Rollins BJ, Yoshimura T, Leonard EJ, et al: Cytokine-activated human endothelial cells synthesize and secrete a monocyte chemoattractant, MCP-1/JE. Am J Pathol 136:1229–1233, 1990.
39. Wang J, Sica A, Peri G, et al: Expression of monocyte chemotactic protein and interleukin-8 by cytokine-activated human vascular smooth muscle cells. Arteriosclerosis 11:1166–1174, 1991.
40. Gu L, Okada Y, Clinton S, et al: Absence of monocyte chemoattractant protein-1 reduces atherosclerosis in low-density lipoprotein-deficient mice. Mol Cell 2:275–281, 1998.
41. Boring L, Gosling J, Cleary M, et al: Decreased lesion formation in CCR2−/− mice reveals a role for chemokines in the initiation of atherosclerosis. Nature 394:894–897, 1998.
42. Nelken N, Coughlin S, Gordon D, et al: Monocyte chemoattractant protein-1 in human atheromatous plaques. J Clin Invest 88:1121–1127, 1991.
43. Mach F, Sauty A, Iarossi A, et al: Differential expression of three T lymphocyte-activating CXC chemokines by human atheroma-associated cells. J Clin Invest 104:1041–1050, 1999.
44. Benditt EP, Benditt JM: Evidence for a monoclonal origin of human atherosclerotic plaques. Proc Natl Acad Sci U S A 70:1753–1756, 1973.
45. Murry CE, Gipaya CT, Bartosek T, et al: Monoclonality of smooth muscle cells in human atherosclerosis. Am J Pathol 151:697–705, 1997.
46. Topper JN, Cai J, Falb D, et al: Identification of vascular endothelial genes differentially responsive to fluid mechanical stimuli: Cyclooxygenase–2, manganese superoxide dismutase, and endothelial cell nitric oxide synthase are selectively up-regulated by steady laminar shear stress. Proc Natl Acad Sci U S A 93:10417–10422, 1996.
47. De Caterina R, Libby P, Peng HB, et al: Nitric oxide decreases cytokine-induced endothelial activation: Nitric oxide selectively reduces endothelial expression of adhesion molecules and proinflammatory cytokines. J Clin Invest 96:60–68, 1995.
48. Peng HB, Libby P, Liao JK: Induction and stabilization of I kappa B alpha by nitric oxide mediates inhibition of NF-kappa B. J Biol Chem 270:14214–14219, 1995.
49. Thurberg B, Collins T: The nuclear factor-kappa B/inhibitor of kappa B autoregulatory system and atherosclerosis. Curr Opin Lipidol 9:387–396, 1998.
50. Schwartz SM, Murry CE: Proliferation and the monoclonal origins of atherosclerotic lesions. Ann Rev Med 49:437–460, 1998.
51. Landerholm TE, Dong XR, Lu J, et al: A role for serum response factor in coronary smooth muscle differentiation from proepicardial cells. Development 126:2053–2062, 1999.
52. Krieger M: The other side of scavenger receptors: Pattern recognition for host defense. Curr Opin Lipidol 8:275–280, 1997.
53. Hajjar DP, Haberland ME: Lipoprotein trafficking in vascular cells. Molecular Trojan horses and cellular saboteurs. J Biol Chem 272:22975–22978, 1997.
54. Sakaguchi H, Takeya M, Suzuki H, et al: Role of macrophage scavenger receptors in diet-induced atherosclerosis in mice. Lab Invest 78:423–434, 1998.
55. Smith JD, Trogan E, Ginsberg M, et al: Decreased atherosclerosis in mice deficient in both macrophage colony-stimulating factor (op) and apolipoprotein E. Proc Natl Acad Sci U S A 92:8264–8268, 1995.
56. Rajavashisth T, Qiao JH, Tripathi S, et al: Heterozygous osteopetrotic (op) mutation reduces atherosclerosis in LDL receptor-deficient mice. J Clin Invest 101:2702–2710, 1998.

THE EVOLUTION OF ATHEROMA

57. Stary HC, Chandler AB, Dinsmore RE, et al: A definition of advanced types of atherosclerotic lesions and a histological classification of atherosclerosis: A report from the Committee on Vascular Lesions of the Council on Arteriosclerosis, American Heart Association. Circulation 92:1355–1374, 1995.
58. Ross R: Atherosclerosis—an inflammatory disease. N Engl J Med 340: 115–126, 1999.
59. Gordon D, Reidy MA, Benditt EP, et al: Cell proliferation in human coronary arteries. Proc Natl Acad Sci U S A 87:4600–4604, 1990.
60. Aikawa M, Kim HS, Kuro-o M, et al: Phenotypic modulation of smooth muscle cells during progression of human atherosclerosis as determined by altered expression of myosin heavy chain isoforms. Ann N Y Acad Sci 748:578–585, 1995.
61. Isner JM, Kearney M, Bortman S, et al: Apoptosis in human atherosclerosis and restenosis. Circulation 91:2703–2711, 1995.
62. Han D, Haudenschild C, Hong M, et al: Evidence for apoptosis in human atherogenesis and in a rat vascular injury model. Am J Pathol 147:267–277, 1995.
63. Geng Y-J, Libby P: Evidence for apoptosis in advanced human atheroma: Co-localization with interleukin-1β-converting enzyme. Am J Pathol 147:251–266, 1995.
64. Geng Y-J, Wu Q, Muszynski M, et al: Apoptosis of vascular smooth muscle cells induced by in vitro stimulation with interferon-gamma, tumor necrosis factor-alpha, and interleukin-1-beta. Arterioscler Thromb Vasc Biol 16:19–27, 1996.
65. Geng Y-J, Henderson L, Levesque E, et al: Fas is expressed in human atherosclerotic intima and promotes apoptosis of cytokine-primed human vascular smooth muscle cells. Arterioscler Thromb Vasc Biol 17: 2200–2208, 1997.
66. Amento EP, Ehsani N, Palmer H, et al: Cytokines positively and negatively regulate interstitial collagen gene expression in human vascular smooth muscle cells. Arteriosclerosis 11:1223–1230, 1991.
67. Dollery CM, McEwan JR, Henney AM: Matrix metalloproteinases and cardiovascular disease. Circ Res 77:863–868, 1995.
68. Libby P: The molecular bases of the acute coronary syndromes. Circulation 91:2844–2850, 1995.
69. Bendeck MP, Irvin C, Reidy MA: Inhibition of matrix metalloproteinase activity inhibits smooth muscle cell migration but not neointimal thickening after arterial injury. Circ Res 78:38–43, 1996.
70. O'Brien ER, Garvin MR, Dev R, et al: Angiogenesis in human coronary atherosclerotic plaques. Am J Pathol 145:883–894, 1994.
71. Brogi E, Winkles J, Underwood R, et al: Distinct patterns of expression of fibroblast growth factors and their receptors in human atheroma and non-atherosclerotic arteries: Association of acidic FGF with plaque microvessels and macrophages. J Clin Invest 92:2408–2418, 1993.
72. Couffinhal T, Kearney M, Witzenbichler B, et al: Vascular endothelial growth factor/vascular permeability factor (VEGF/VPF) in normal and atherosclerotic human arteries. Am J Pathol 150:1673–1685, 1997.

73. Ramos MA, Kuzuya M, Esaki T, et al: Induction of macrophage VEGF in response to oxidized LDL and VEGF accumulation in human atherosclerotic lesions. Arterioscler Thromb Vasc Biol 18:1188–1196, 1998.
74. Vasse M, Pourtau J, Trochon V, et al: Oncostatin M induces angiogenesis in vitro and in vivo. Arterioscler Thromb Vasc Biol 19:1835–1842, 1999.
75. O'Brien K, Allen M, McDonald T, et al: Vascular cell adhesion molecule-1 is expressed in human coronary atherosclerotic plaques: Implications for the mode of progression of advanced coronary atherosclerosis. J Clin Invest 92:945–951, 1993.
76. Moulton KS, Heller E, Konerding MA, et al: Angiogenesis inhibitors endostatin or TNP-470 reduce intimal neovascularization and plaque growth in apolipoprotein E-deficient mice. Circulation 99:1726–1732, 1999.
77. Demer LL: A skeleton in the atherosclerosis closet. Circulation 92: 2029–2032, 1995.

COMPLICATIONS OF ATHEROSCLEROSIS

78. Bruschke AV, Kramer J Jr, Bal ET, et al: The dynamics of progression of coronary atherosclerosis studied in 168 medically treated patients who underwent coronary arteriography three times. Am Heart J 117:296–305, 1989.
79. Yokoya K, Takatsu H, Suzuki T, et al: Process of progression of coronary artery lesions from mild or moderate stenosis to moderate or severe stenosis: A study based on four serial coronary arteriograms per year. Circulation 100:903–909, 1999.
80. Falk E, Shah P, Fuster V: Coronary plaque disruption. Circulation 92: 657–671, 1995.
81. Smith S Jr: Risk–reduction therapy: The challenge to change. Circulation 93:2205–2211, 1996.
82. Hackett D, Davies G, Maseri A: Pre-existing coronary stenoses in patients with first myocardial infarction are not necessarily severe. Eur Heart J 9:1317–1323, 1988.
83. Ziada KM, Kapadia SR, Tuzcu EM, et al: The current status of intravascular ultrasound imaging. Curr Probl Cardiol 24:541–566, 1999.
84. Davies MJ: Stability and instability: The two faces of coronary atherosclerosis. The Paul Dudley White Lecture, 1995. Circulation 94:2013–2020, 1996.
85. Farb A, Burke A, Tang A, et al: Coronary plaque erosion without rupture into a lipid core: A frequent cause of coronary thrombosis in sudden coronary death. Circulation 93:1354–1363, 1996.
86. Burke A, Farb A, Malcom G, et al: Coronary risk factors and plaque morphology in men with coronary disease who died suddenly. N Engl J Med 336:1276–1282, 1997.
87. Burke AP, Farb A, Malcom GT, et al: Effect of risk factors on the mechanism of acute thrombosis and sudden coronary death in women. Circulation 97:2110–2116, 1998.
88. Lee R, Libby P: The unstable atheroma. Arterioscler Thromb Vasc Biol 17:1859–1867, 1997.
89. Henney AM, Wakeley PR, Davies MJ, et al: Localization of stromelysin gene expression in atherosclerotic plaques by in situ hybridization. Proc Natl Acad Sci U S A 88:8154–8158, 1991.
90. Galis Z, Sukhova G, Lark M, et al: Increased expression of matrix metalloproteinases and matrix degrading activity in vulnerable regions of human atherosclerotic plaques. J Clin Invest 94:2493–2503, 1994.
91. Sukhova GK, Shi GP, Simon DI, et al: Expression of the elastolytic cathepsins S and K in human atheroma and regulation of their production in smooth muscle cells. J Clin Invest 102:576–583, 1998.
92. Lendon CL, Davies MJ, Born GV, et al: Atherosclerotic plaque caps are locally weakened when macrophages density is increased. Atherosclerosis 87:87–90, 1991.
93. Loree HM, Kamm RD, Stringfellow RG, et al: Effects of fibrous cap thickness on peak circumferential stress in model atherosclerotic vessels. Circ Res 71:850–858, 1992.
94. Davies MJ, Richardson PD, Woolf N, et al: Risk of thrombosis in human atherosclerotic plaques: Role of extracellular lipid, macrophage, and smooth muscle cell content. Br Heart J 69:377–381, 1993.
95. Loree HM, Tobias BJ, Gibson LJ, et al: Mechanical properties of model atherosclerotic lesion lipid pools. Arterioscler Thromb 14:230–234, 1994.
96. Cheng GC, Loree HM, Kamm RD, et al: Distribution of circumferential stress in ruptured and stable atherosclerotic lesions: A structural analysis with histopathologic correlation. Circulation 87:1179–1187, 1993.
97. Libby P, Lee R: Role of activated macrophages and T lymphocytes in rupture of coronary plaques. *In* Braunwald E (ed): Heart Disease: A Textbook of Cardiovascular Medicine. Update. Vol 2. Philadelphia, WB Saunders, 1995.
98. Aikawa M, Rabkin E, Okada Y, et al: Lipid lowering by diet reduces matrix metalloproteinase activity and increases collagen content of rabbit atheroma: A potential mechanism of lesion stabilization. Circulation 97:2433–2444, 1998.
99. Aikawa M, Rabkin E, Voglic SJ, et al: Lipid lowering promotes accumulation of mature smooth muscle cells expressing smooth muscle myosin heavy chain isoforms in rabbit atheroma. Circ Res 83:1015–1026, 1998.
100. Aikawa M, Voglic SJ, Sugiyama S, et al: Dietary lipid lowering reduces tissue factor expression in rabbit atheroma. Circulation 100:1215–1222, 1999.
101. Ridker PM, Rifai N, Pfeffer MA, et al: Long–term effects of pravastatin on plasma concentration of C-reactive protein: The Cholesterol and Recurrent Events (CARE) Investigators. Circulation 100:230–235, 1999.
102. Faggiotto A, Ross R: Studies of hypercholesterolemia in the nonhuman primate: II. Fatty streak converstion to fibrous plaque. Arteriosclerosis 4:341–356, 1984.

MECHANISMS OF RESTENOSIS AND IN-STENT STENOSIS

103. McNamara CA, Sarembock IJ, Gimple LW, et al: Thrombin stimulates proliferation of cultured rat aortic smooth muscle cells by a proteolytically activated receptor. J Clin Invest 91:94–98, 1993.
104. Ip JH, Fuster V, Badimon L, et al: Syndromes of accelerated atherosclerosis: Role of vascular injury and smooth muscle cell proliferation. J Am Coll Cardiol 15:1667–1687, 1990.
105. Fingerle J, Johnson R, Clowes AW, et al: Role of platelets in smooth muscle cell proliferation and migration after vascular injury in rat carotid artery. Proc Natl Acad Sci U S A 86:8412–8416, 1989.
106. Lindner V, Reidy MA: Proliferation of smooth muscle cells after vascular injury is inhibited by an antibody against basic fibroblast growth factor. Proc Natl Acad Sci U S A 88:3739–3743, 1991.
107. Lindner V: Role of basic fibroblast growth factor and platelet-derived growth factor (B-chain) in neointima formation after arterial injury. Z Kardiol 4:137–144, 1995.
108. Mintz GS, Popma JJ, Pichard AD, et al: Arterial remodeling after coronary angioplasty: A serial intravascular ultrasound study. Circulation 94:35–43, 1996.
109. Libby P, Schwartz D, Brogi E, et al: A cascade model for restenosis, a special case of atherosclerosis progression. Circulation 86(III):47–52, 1992.
110. Tanaka H, Sukhova G, Swanson S, et al: Sustained activation of vascular cells and leukocytes in the rabbit aorta after balloon injury. Circulation 88:1788–1803, 1993.

ACCELERATED ARTERIOSCLEROSIS IN TRANSPLANTED ORGANS

111. Libby P: Transplantation–associated arteriosclerosis: Potential mechanisms. *In* Tilney N, Strom T (eds): Transplantation Biology. Philadelphia, Lippincott-Raven, 1996, pp 577–586.
112. Billingham ME: Histopathology of graft coronary disease. J Heart Lung Transplant 11:s38–s44, 1992.
113. Tuzcu EM, De Franco AC, Goormastic M, et al: Dichotomous pattern of coronary atherosclerosis 1 to 9 years after transplantation: Insights from systematic intravascular ultrasound imaging. J Am Coll Cardiol 27:839–846, 1996.
114. Salomon RN, Hughes CCW, Schoen FJ, et al: Human coronary transplantation-associated arteriosclerosis: Evidence for a chronic immune reaction to activated graft endothelial cells. Am J Pathol 138:791–798, 1991.
115. Nagano H, Mitchell RN, Taylor MK, et al: Interferon–gamma deficiency prevents coronary arteriosclerosis but not myocardial rejection in transplanted mouse hearts. J Clin Invest 100:550–557, 1997.

ANEURYSMAL DISEASE

116. Strong JP, Malcom GT, Oalmann MC, et al: The PDAY Study: Natural history, risk factors, and pathobiology: Pathobiological Determinants of Atherosclerosis in Youth (PDAY) Research Group. Ann N Y Acad Sci 811:226–235, 1997.
117. McGill HC Jr, McMahan CA: Determinants of atherosclerosis in the young:. Pathobiological Determinants of Atherosclerosis in Youth (PDAY) Research Group. Am J Cardiol 82:30t–36t, 1998.
118. Komatsu A, Sakurai I: A study of the development of atherosclerosis in childhood and young adults: Risk factors and the prevention of progression in Japan and the USA: The Pathobiological Determinants of Atherosclerosis in Youth (PDAY) Research Group. Pathol Int 46:541–547, 1996.
119. Freestone T, Turner RJ, Coady A, et al: Inflammation and matrix metalloproteinases in the enlarging abdominal aortic aneurysm. Arterioscler Thromb Vasc Biol 15:1145–1151, 1995.
120. Tamarina NA, McMillan WD, Shively VP, et al: Expression of matrix metalloproteinases and their inhibitors in aneurysms and normal aorta. Surgery 122:264–271, 1997.
121. Knox JB, Sukhova GK, Whittemore AD, et al: Evidence for altered balance between matrix metalloproteinases and their inhibitors in human aortic diseases. Circulation 95:205–212, 1997.
122. McMillan WD, Pearce WH: Inflammation and cytokine signaling in aneurysms. Ann Vasc Surg 11:540–545, 1997.
123. Henderson EL, Geng YJ, Sukhova GK, et al: Death of smooth muscle cells and expression of mediators of apoptosis by T lymphocytes in human abdominal aortic aneurysms. Circulation 99:96–104, 1999.

POSSIBLE ROLES FOR INFECTIOUS AGENTS IN ATHEROSCLEROSIS

124. Danesh J, Collins R, Peto R: Chronic infections and coronary heart disease: Is there a link? Lancet 350:430–436, 1997.

125. Libby P, Egan D, Skarlatos S: Roles of infectious agents in atherosclerosis and restenosis: An assessment of the evidence and need for future research. Circulation 96:4095–4103, 1997.
126. Ridker PM: Are associations between infection and coronary disease causal or due to confounding? Am J Med 106:376–377, 1999.
127. Gaydos CA, Summersgill JT, Sahney NN, et al: Replication of *Chlamydia pneumoniae* in vitro in human macrophages, endothelial cells, and aortic artery smooth muscle cells. Infect Immun 64:1614–1620, 1996.
128. Kol A, Sukhova G, Lichtman A, et al: Chlamydial heat shock protein 60 localizes in human atheroma and regulates macrophage TNF-alpha and matrix metalloproteinase expression. Circulation 98:300–307, 1998.
129. Kol A, Bourcier T, Lichtman AH, et al: Chlamydial and human heat shock protein 60s activate human vascular endothelium, smooth muscle cells, and macrophages. J Clin Invest 103:571–577, 1999.
130. Kalayoglu MV, Byrne GI: Induction of macrophage foam cell formation by *Chlamydia pneumoniae.* J Infect Dis 177:725–729, 1998.
131. Kalayoglu MV, Byrne GI: A *Chlamydia pneumoniae* component that induces macrophage foam cell formation is chlamydial lipopolysaccharide. Infect Immun 66:5067–5072, 1998.
132. Kalayoglu MV, Hoerneman B, LaVerda D, et al: Cellular oxidation of low-density lipoprotein by *Chlamydia pneumoniae.* J Infect Dis 180: 780–790, 1999.
133. Kol A, Lichtman AH, Finberg RW, et al: Heat shock protein (HSP) 60 activates the innate immune response: CD14 is an essential receptor for HSP60 activation of mononuclear cells. J Immunol 164:13–17, 2000.
134. Fleet JC, Clinton SK, Salomon RN, et al: Atherogenic diets enhance endotoxin-stimulated interleukin-1 and tumor necrosis factor gene expression in rabbit aortae. J Nutr 122:294–305, 1992.