

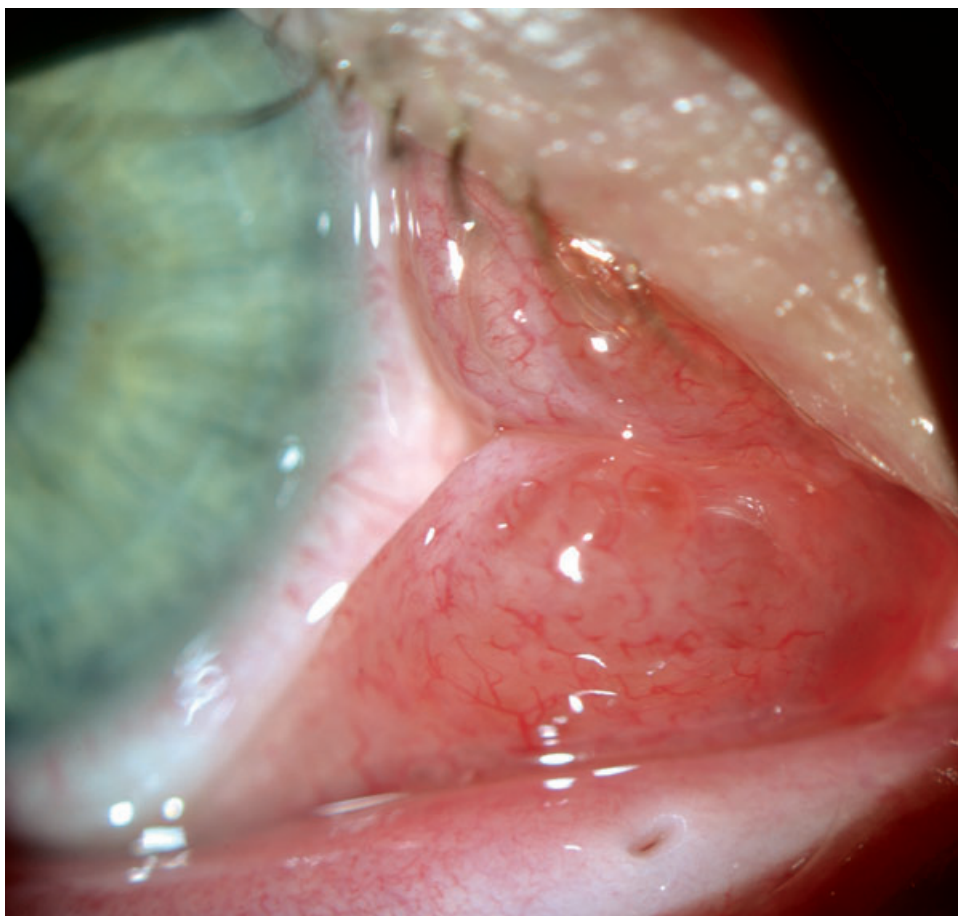Fig. 5.38 Lymphangioma within the conjunctiva. This is another example of a lymphangioma within the conjunctiva. These lesions are characteristically multiloculated and contain cystic channels.

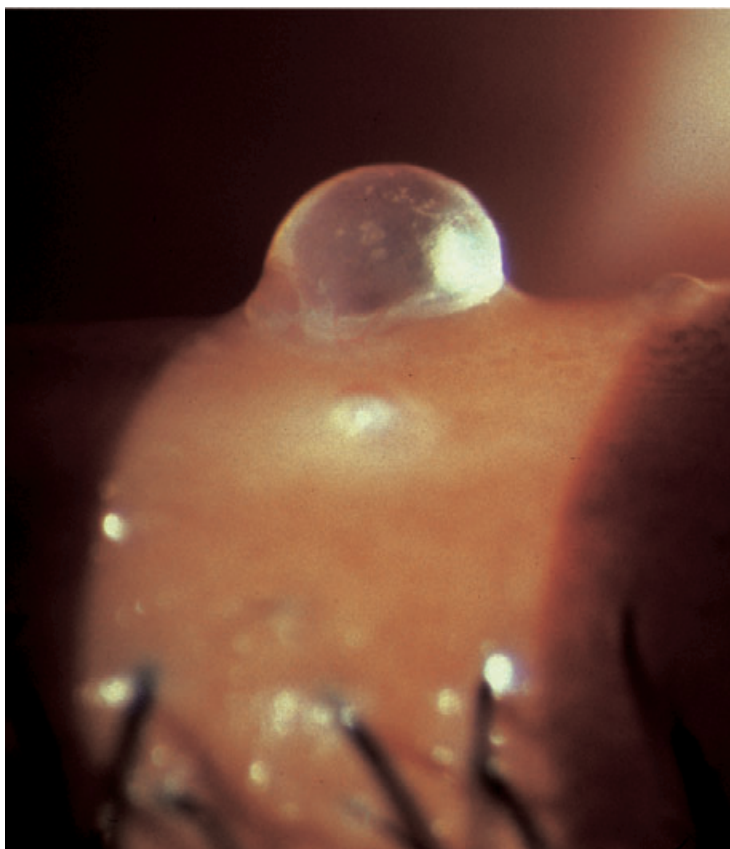


Fig. 5.39 Lymphangioma involving the lid. This patient has lid and orbital involvement.

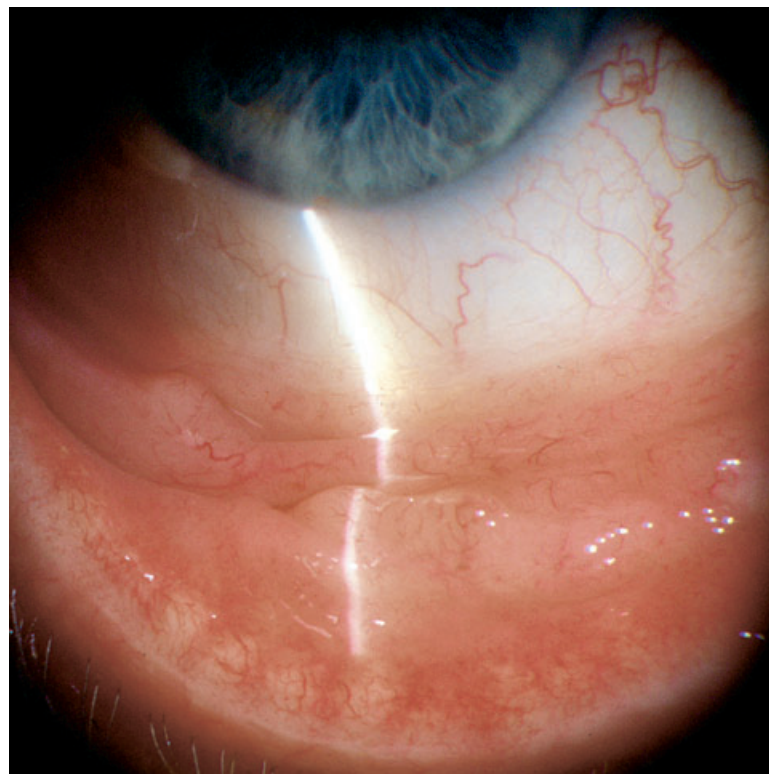


Fig. 5.40 Benign lymphoid hyperplasia. Lymphoid lesions of the conjunctiva are typically elevated and salmon-colored. The surrounding tissue is uninfamed. A local biopsy is necessary to establish the diagnosis.